

Original Research Article

Volume 13 Issue 2

Feb 2024

SULPHUR - "KING OF ANTIPSORICS"

Dr Mohammed Ramees Sabu C K

Mentor, Dr Batra's Positive Health Clinic Pvt. Ltd., Vijaynagar, Bangalore, India

Email id: drramees.ck@drbatras.com

Abstract

Eczema, a persistent inflammatory skin condition, poses a continuous challenge for both patients and practitioners. This abstract explores the effectiveness of Sulphur, renowned as the "King of Antipsorics" in homeopathy, by analyzing five compelling eczema cases. Sulphur, sourced from minerals, particularly known for its profound affinity for the skin, marked by intense itching and burning sensations. It is highly regarded for its potential to address the underlying psoric miasm, emphasizing a holistic approach to healing. This paper illustrates examination of five distinct eczema cases, this series demonstrates Sulphur's remarkable success in restoring balance not only to alleviate the physical symptoms of eczema but also to address chronic tendencies contributing to the condition, resulting in an overall improvement in patients' well-being.

Keywords: Eczema, Homeopathy, Psoric, Sulphur

Introduction

Sulphur, a fundamental homeopathic remedy, holds the title of the "King of Antipsorics." Derived from mineral sources, Sulphur plays a pivotal role when there is a profound underlying psoric miasm, stemming from a predisposition to skin disorders, digestive issues, and constitutional imbalances. It is often prescribed when symptoms manifest due to suppressed eruptions or chronic ailments. **Skin Affinity:** Sulphur exhibits a marked affinity for the skin, presenting symptoms such as intense itching, burning sensations, and various skin eruptions.

Digestive Disturbances: Gastrointestinal symptoms, including acidity, flatulence, and a sensation of fullness, are common indications for Sulphur.

Psychological Aspects: Individuals needing Sulphur may display a carefree and indifferent attitude, often avoiding personal hygiene.

While Sulphur is valuable in addressing chronic conditions, its inappropriate or prolonged use can lead to potential complications. These may include aggravation of symptoms, increased susceptibility to certain ailments, or the development of new and more complex health issues.

Case Profile

CASE NO: 1	
Presenting Complaints	C/O 5 YRS KID PRESENTED WITH ALLERGIC ECZEMA ON UNDER EYE WITH REDISH DRY RASHES AND SEVERE ITCHING SINCE ALMOST 1 YEAR. COLD CLIMATE AGGRAVATION. P/H ALLERGIC RHINITIS SNEEZING AND NOSE BLOCKAGE. ONCE SKIN RASHES COME NO URT
Treatment history	TACRO ointment - temporary relief
Family history	Mother – Eczema
Physical generals	Appetite: Normal, Craves: Sweets, Sleep: Right, Stool: Normal, Urine: Normal
Mental generals	Extroverted, Very active, Has a mentality to win, Appreciates and is very sensitive to criticism, Has his own dreams and thoughts, Dislikes forcing, impatient, Fear of darkness, Enjoys fight movies
Observations/Examination	WOODSLAMP: No relevance Naked eye examination shows reddish under-eye
Prescription	Started with Phos 30 single dose then intercurrent antipsoric SULPHUR 200 water dose single dose.
Follow up	Started with Phos - no changes. Given SULPHUR 200, started responding, itching reduced, redness reduced, CURED

CASE NO: 2	
Presenting Complaints	C/O 15 /F KID PRESENTED WITH ALLERGIC ECZEMA ON PALMS WITH ITCHING AND SCALING SINCE LONG. EVERY WINTER IT AGGRAVATED. P/H: NO ILLNESS. T/H: MOISTURIZING LOTIONS. F/H: NP
Physical generals	Appetite: Normal Craves: Spicy Sleep: Left Stool: Normal Urine: Normal
Mental generals	Ambiverted in nature Talks if needed Active in school Lean thin constitution Sensitive and emotional Dislikes consolation Anger for small trifles
Observations/Examination	WOODSLAMP: Mild flaky skin on palms
Prescription	Started with constitutional SULPHUR 200 in water dose as antipsoric symptoms.
Follow up	Started responding, itching reduced rashes reduced CURED

CASE NO: 3	
Presenting Complaints	C/O 26/M PRESENTED WITH ECZEMA WITH ITCHING AND OOZING ON ANKLE, SHIN, AND FOREARMS SINCE 5 YEARS. WET SOME TIME, SOME TIME DRYNESS. WHEN CLIMATE GETS COLD IT AGGRAVATES
Physical generals	Appetite: Normal Craves: Sweet Sleep: Good Stool: Normal Urine: Normal
Mental generals	Introverted person Takes time to mingle with people A good listener Yielding person Mild anger easily for small things Consolation ameliorates Sensitive to open air

	Sleep normal Left-sided sleep Emotional person
Observations/Examination	WOODSLAMP: Mild reddish oozing eczema
Prescription	Started with CALC SULPH, no changes, it was increasing. Administered SULPHUR 200 as water dose, started responding, and cured
Follow up	Started responding, itching reduced rashes reduced CURED

CASE NO: 4

Presenting Complaints	C/O 4 YR KID PRESENTED IN FOLLOW-UP CASE OF ALLERGIC RHINITIS WITH ECZEMA. REDDISH ITCHY ERUPTION ON RT ELBOW JOINT FLEXOR ASPECT INTOLERABLE ITCHING. AGGRAVATION IN CLIMATE
Treatment history	ALLOPATHIC CREAMS, WHICH INTERNALLY TRIGGERS ALLERGIC RHINITIS
Physical generals	Appetite: Normal Craves: Sweet Sleep: Good Stool: Normal Urine: Normal
Mental generals	Calm, quiet, shy, does not mingle easily, at school has only 3-4 friends among 30 classmates, obedient, not stubborn, wants to be pampered, did not allow breastfeeding to be stopped till 2 years. Maternal history stressed due to son having a brain tumor. Anxious during pregnancy. Put on only 2-3 kgs in pregnancy
Observations/Examination	WOODSLAMP: Reddish rashes over hands
Prescription	Started with constitutional SULPHUR 200 in water dose as antipsoric symptoms. Follow-up: Responded

CASE NO: 5

Presenting Complaints	C/O 41/m REDDISH SCALY PSORIATIC ERUPTIONS SINCE 1 YEAR. LOCATION-CHEST, ABDOMEN, UPPER AND LOWER BACK, SCALP. ITCHING AND PAINFUL. DRYNESS OF SKIN PRESENT. SCALY FLAKES IN SCALP AND IN MARGIN OF HAIR. SAYS AFTER COVID
-----------------------	---

	VACCINATION PSORIASIS STARTED. USED ALLOPATHY Clobetasol Propionate lotion. CURRENTLY USING AYURVEDIC MEDICATIONS
Treatment history	ALLOPATHIC CREAMS, WHICH INTERNALLY TRIGGERS ALLERGIC RHINITIS
Physical generals	COVID VACCINATION – physical trigger Appetite: Good, Bowels: Constipated irregular, Thirst: 2-3 liters, Diet: Non-veg, Sleep: Disturbed due to skin issues. Habits: Smoking but now stopped
Mental generals	Business downfall in COVID lockdown Ambiverted, dirty-looking constitution, keeps distance shares emotions with one or two people dislikes consolation, easily angered by small mistakes, shout for very small reasons, business downfall during COVID, after COVID, during this condition began after vaccines
Observations/Examination	WOODSLAMP: Whitish flakes, reddish round patches on back
Prescription	Started with NUX VOMICA as a physical trigger considering ailment from allopathic remedy and vaccination. No changes, patient was complaining and squint. Then constitution-based on antisporic symptoms given SULPHUR 200 water dose single dose.
Follow up	Responded and cured

Case analysis

Rubrics from the above case histories

Mind, Delusions, Imaginations, winning, about

Mind, Company, aversion to, intolerance of

Mind, Dreams, winning

Mind, Fear, darkness

Mind, Dreams, fight

Mind, Impatient

Mind, Dreams, fighting

Mind, Dreams, fighting, winning

Skin, Eruptions, eczema, children, in

Skin, Eruptions, itching, cold air, agg.

Miasmatic approach

Symptoms	Psor a	Sycosi s	Syphili s	Tubercula r
Mind, Delusions, Imaginations, winning, about	+			
Mind, Company, aversion to, intolerance of	+			
Mind, Dreams, winning	+			
Mind, Fear, darkness	+			
Mind, Dreams, fight	+			
Mind, Impatient	+			
Mind, Dreams, fighting	+			
Mind, Dreams, fighting, winning	+			
Skin, Eruptions, eczema, children, in	+			
Skin, Eruptions, itching, cold air, agg.	+			

Results

CASE NO.	FOLLOW-UP	SYMPTOMS	PRESCRIPTION	PROGRESS
1	1st	- Severe itching and dry rashes under the eye - Cold climate aggravation - Allergic rhinitis with sneezing and nose blockage	Phos 30 single dose	No significant changes
	2nd	- Continuing symptoms - Administered SULPHUR 200 water dose	SULPHUR 200 water dose	Itching reduced, redness reduced, CURED
2	1st	- Itching and scaling on palms, aggravated in winter - Moisturizing lotions provided temporary relief	SULPHUR 200 water dose as antipsoric symptoms	Responding, itching and rashes cured
	2nd	- Improvement in symptoms	-	Further improvement
3	1st	- Eczema with itching and oozing on ankle, shin, and forearms - Wet and dry at times - Aggravated in cold climate	CALC SULPH initially, later SULPHUR 200 water dose	No improvement with CALC SULPH, responded to SULPHUR
	2nd	- Improvement observed	-	Cured

4	1st	- Allergic rhinitis with eczema on the right elbow joint - Intolerable itching - Aggravation in climate	SULPHUR 200 water dose as antipsoric symptoms	Responded, improvement in symptoms
	2nd	- Improvement observed	-	Further improvement
5	1st	- Reddish, scaly psoriatic eruptions on chest, abdomen, upper and lower back, scalp - Itching and painful - Dry skin with flakes	NUX VOMICA initially, SULPHUR 200 water dose as antipsoric symptoms	No changes with NUX VOMICA, responded to SULPHUR
	2nd	- Improvement observed	-	Cured

Discussion & Conclusion

The presented cases highlight the efficacy of homeopathic treatment in managing various dermatological conditions, particularly eczema and psoriasis. In Case 1, the utilization of Phosphorus and Sulphur demonstrated a successful approach in alleviating allergic eczema symptoms. The constitutional prescription followed by an intercurrent antipsoric resulted in a significant reduction in itching and redness.

Case 2 involved a 15-year-old with recurrent eczema on the palms aggravated during winters. A constitutional prescription of Sulphur 200 water dose, considering antipsoric symptoms, led to substantial improvement, emphasizing the role of individualized treatment.

In Case 3, a 26-year-old presented with eczema on the ankle, shin, and forearms, showcasing the importance of selecting the right antipsoric remedy. Initial administration of Calcarea Sulphur failed to yield results, while Sulphur 200 water dose addressed the case effectively. Case 4 highlighted the interconnectedness of allergic rhinitis and eczema. A thorough understanding of the patient's mental and physical state guided the prescription of Sulphur 200 water dose as an antipsoric, resulting in remarkable progress.

Case 5, involving psoriatic eruptions post-COVID vaccination, showcased the significance of identifying physical triggers. The prescription evolved from Nux Vomica to Sulphur 200

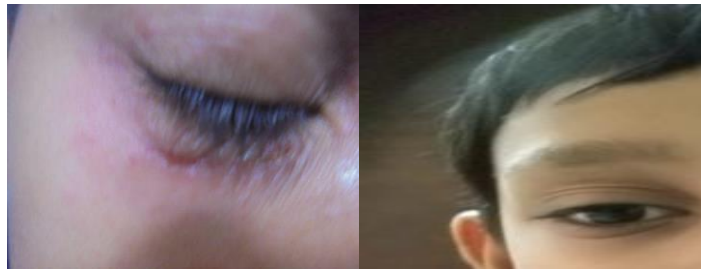
water dose based on the patient's response, providing relief and ultimately curing the condition.

These cases underscore the holistic and individualized approach of homeopathy in treating dermatological disorders. The selection of remedies based on constitutional and miasmatic considerations, coupled with a keen understanding of mental symptoms, played a pivotal role in achieving positive outcomes. The versatility of Sulphur, a key antipsoric remedy, was evident across cases, demonstrating its effectiveness in addressing chronic tendencies and promoting overall well-being. The successful management of eczema and psoriasis in these cases reinforces the potential of homeopathy as a valuable therapeutic option for dermatological conditions.

The transformation

Attach before and after treatment photographs/investigations here

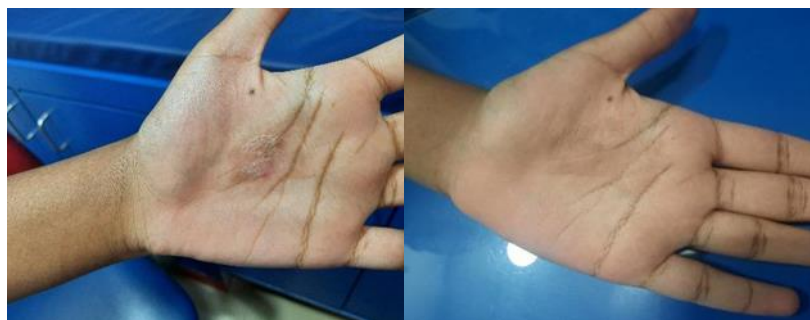Case 1



BEFORE

AFTER

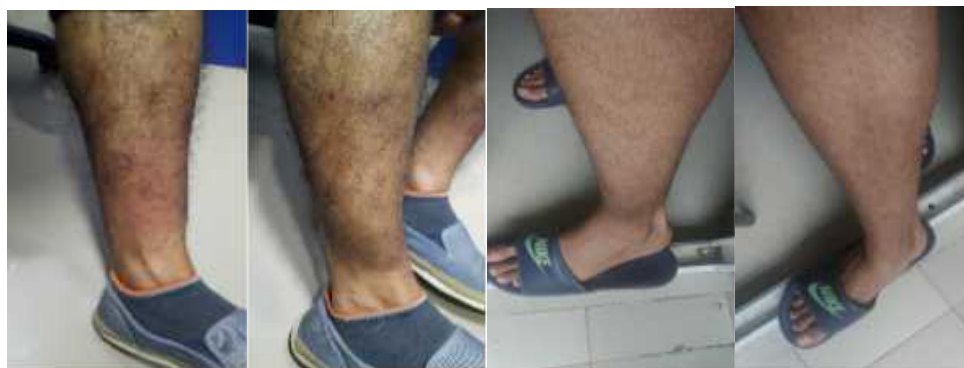Case 2



BEFORE

AFTER

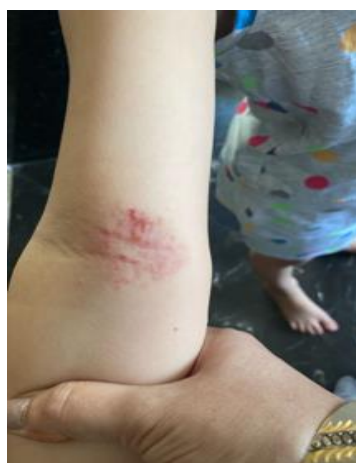Case 3



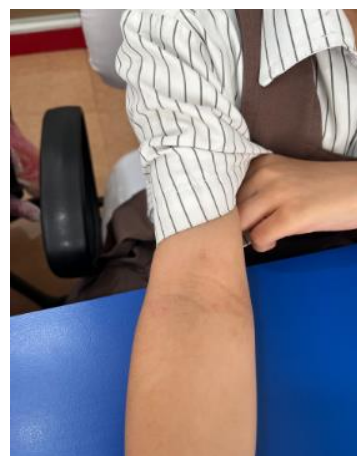BEFORE

AFTER

case 4

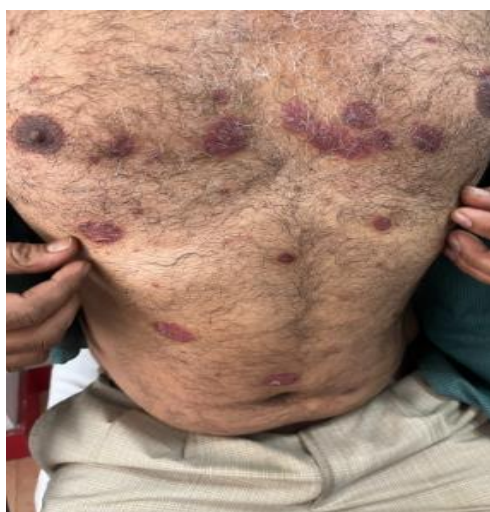

BEFORE

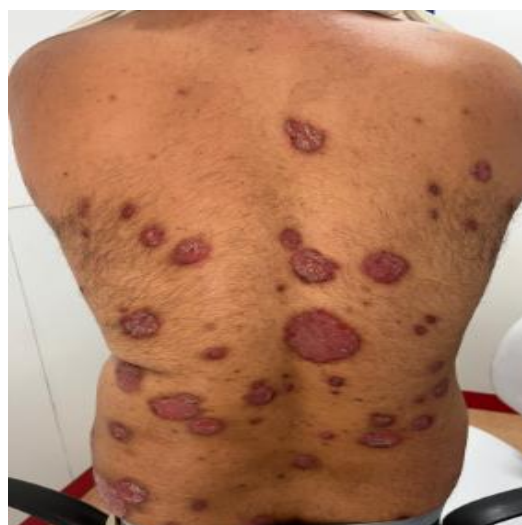

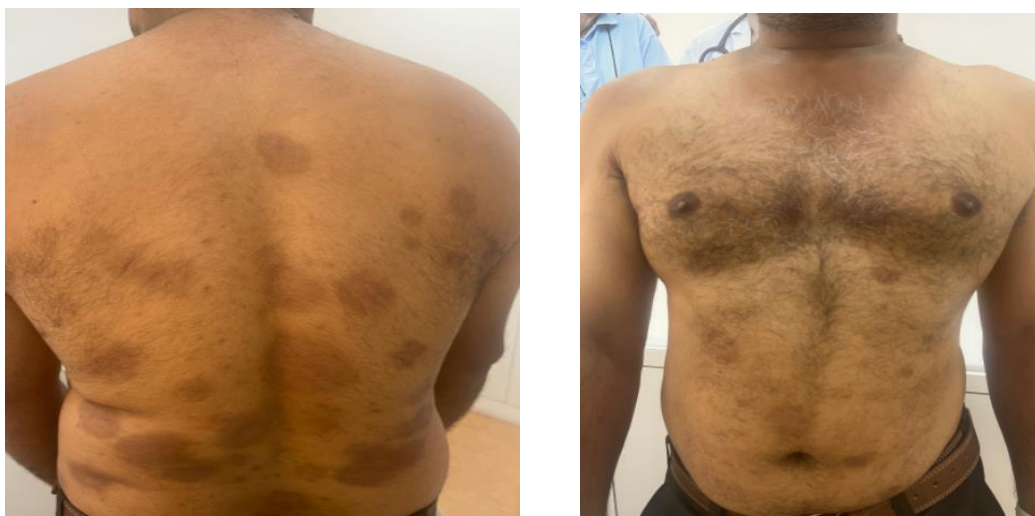AFTER

Case 5



BEFORE





AFTER

Acknowledgments

I express my heartfelt thanks to Dr. Batra's Positive Health Clinic for offering me a platform and resources to extend the healing touch. A special acknowledgment to Dr. Mukesh Batra, the founder of Dr. Batra's Positive Health Clinic, Gratitude to MD Dr. Akshay Batra for his unwavering commitment to quality. I am thankful to CEO Mr. Sanjoy Mukerji for his sharp direction, motivation, and guidance, Dr. Bindu Sharma, Director at Dr. Batra's, receives my sincere thanks for her constant guidance and strong support for me and my entire medical team. Special appreciation to Dr. Daniel Raj for mentoring, guiding, and inspiring me throughout these 5 years. I extend my thanks to the entire team at Dr. Batra's HSR and Vijayanagar branches for their contributions to these cases, and to Dr. Tanvi Lokhande for her editorial assistance in completing this case.