



Original Research Article

Volume 15 Issue 06

June 2026

HOLISTIC HOMEOPATHIC ANALYSIS OF A CASE OF CHRONIC ORAL LICHEN PLANUS

Dr Shireen Sayed

Designation - CHC cum Mentor, Branch name, - Malleswaram

Dr Batra's Positive Health Clinic Pvt. Ltd., Qualification-MD,Trichologist

Email id- drshireen.sayed@drbatras.com, Mobile-9986358482

I. Case Identification

- **Patient:** Male, 41 years
- **Residence:** Bangalore (originally from Rajasthan)
- **Occupation:** Stationery shop salesman
- **Duration of complaints:** Oral lichen planus – 2 years; hypothyroidism – 2 years; anal fissure – 6 months
- **Date of first consultation:** 26 February 2025

II. Presenting Complaints

1. **Burning pain in mouth**, < spicy or sour food
2. **Pricking sensation** in buccal mucosa
3. **Oral mucosal patches**, whitish-blackish discoloration, left buccal mucosa predominant
4. **Anal fissure** – burning and pain during defecation (earlier)
5. **Dryness of mouth**, occasional sensitivity
6. **No relief from steroids**, hence seeking alternative treatment

III. Associated Complaints

- **Catarrhal irritation in eyes** with mucous discharge
- **Hypothyroidism** (TSH 26 μ IU/mL) with lethargy and mild weight gain
- **Forgetfulness**, absent-mindedness
- **Occasional mild anxiety and restlessness**

IV. Past History

- Took **steroids** earlier → temporary relief → relapse
- History of mild **hookah smoking** (stopped 4–5 years ago)

V. Family History

- **Father:** Hypertension, diabetes mellitus
- **Mother:** Suicide when patient was 3 years old (strong emotional imprint)
- **Step-mother:** Strained emotional background
- **No hereditary skin or autoimmune disorder**

VI. Personal History

- **Diet:** Vegetarian, Jain
- **Appetite:** Normal
- **Thirst:** 1–2 litres/day
- **Sleep:** Sound
- **Bowels:** Regular
- **Urine:** Normal
- **Physical activity:** Sedentary
- **Habits:** Hookah (past), no alcohol/tobacco now

VII. Mental Generals

- **Core emotion:** Anxiety with deep-seated insecurity
- **Personality:** Responsible, fastidious, sensitive, seeks reassurance
- **Stressors:** Financial worries, family duties, early childhood deprivation
- **Behavioral traits:**

- Anxious about health, money, and family
- Tendency to brood over disappointments
- Fear of disease aggravation
- Easily fatigued mentally
- **Memory:** Forgetful, absent-minded (mental dullness post-thyroid dysfunction)
- **Temperament:** Mild, anxious, reserved; worries about future and responsibilities
- **Reaction to stress:** Internalizes emotions → psychosomatic flare-up

VIII. Physical Generals

| Parameter | Observation |
|----------------------|--|
| Thermal state | Chilly, desires warmth |
| Appetite | Adequate |
| Thirst | Moderate |
| Sleep | Sound |
| Perspiration | Normal |
| Desires | Warm food, mild spice |
| Aversions | Spicy, sour foods (due to aggravation) |
| Aggravations | Spices, sour food, emotional stress, summer heat |
| Ameliorations | Warmth, bland food, rest, reassurance |

IX. Particulars

| Particular | Description |
|----------------|---|
| Mouth | Burning, raw sensation, < spicy/sour; blackish patches left buccal mucosa |
| Rectum | Anal fissure, burning and pain during stool; better now |
| Skin | No eruptions elsewhere, mild itching around oral lesions |
| Thyroid | Hypothyroid trend, improved clinically with homeopathic medication |
| Eyes | Catarrhal discharge, mild irritation |

X. Causation (Etiology)

- **Emotional suppression and stress** from childhood trauma and current financial worries
- **Autoimmune tendency** (Hypothyroidism + Oral LP)
- **Suppressed eruptions** or iatrogenic suppression by corticosteroids

XI. Diagnosis (Clinical)

- **Oral Lichen Planus (OLP)**
- **Hypothyroidism (Autoimmune – Hashimoto trend likely)**
- **Anal fissure secondary to constipation**

XII. Miasmatic Analysis

| Level | Evidence |
|------------------------|---|
| Psoric | Hypersensitivity to stress, dryness, fissures, itching, anxiety, craving for warmth |
| Syphilitic | Destructive pathology of oral mucosa, ulceration, discoloration |
| Syco-Psoric | Hypothyroidism (endocrine sluggishness), infiltration of mucosa |
| Dominant miasm: | Psoro-syphilitic , with latent sycotic tendencies |

XIII. Totality of Symptoms

1. Anxiety about health, family, and finances
2. Forgetfulness, dullness of memory
3. Burning pain in mouth < spicy/sour food
4. Blackish, ulcerated mucosal lesions (left buccal mucosa)
5. Fissure in anus, burning during stool (earlier)
6. Catarrhal discharge from eyes
7. Hypothyroidism with sluggishness
8. Chilly patient, desires warmth

9. < Summer; > Warmth, bland diet
10. History of grief and early emotional loss

XIV. Remedy Analysis

Remedy 1: Arsenicum album (*Constitutional + Acute*)

Key Correspondences:

- Anxiety with insecurity about health and finances
- Burning pains relieved by warmth
- Fastidious, neat, cautious, sensitive to disorder
- Blackish discolorations of mucous membranes
- Hypersensitivity of oral mucosa, < spicy food
- Restlessness, anxious yet exhausted
- Suits chilly, debilitated constitutions

Confirmatory Symptoms:

- Mental restlessness with meticulous habits
- Burning pains > warmth
- Complaints after grief, loss, or financial worries

Hence, *Arsenicum album 200C* prescribed as **constitutional** and **acute** phase remedy.

Remedy 2: Sulphur (*Intercurrent*)

Rationale:

To clear psoric miasmatic blocks and sustain improvement in chronic mucosal inflammation.

Key Traits:

- Chronic tendency to mucocutaneous eruptions
- Heat, dryness, burning in mouth and anus
- Intellectual but forgetful, careless in habits
- Used as a complementary to *Arsenicum album* to balance psoric depth

Given as **200C**, fortnightly, intercurrent remedy.

XV. Course of Treatment

| Date | Observation | Remedy Given |
|-------------|--|--|
| 26 Feb 2025 | Burning mouth, fissure pain; anxious | <i>Ars. alb</i> 200C daily x 15 days |
| 01 Apr 2025 | Burning reduced; fissure healing | Continued <i>Ars. alb</i> weekly |
| 26 Apr 2025 | Temporary aggravation | Diet correction, same remedy |
| 09 Jun 2025 | Stable, no new lesions, thyroid better | Added <i>Sulphur</i> 200C intercurrent |
| 03 Jul 2025 | Improved, no new lesions | Continued <i>Sulphur</i> fortnightly |
| 01 Aug 2025 | Mild aggravation while chewing | <i>Ars. alb</i> single dose |
| 06 Sep 2025 | Feels better, fissure healed | Maintain same |
| 01 Oct 2025 | Stable remission | Continued observation |

XVI. Repertorial Highlights

Rubrics Considered:

1. Mind – Anxiety – health, about
2. Mind – Forgetfulness
3. Mouth – Pain – burning – food, spicy, from
4. Mouth – Discoloration – blackish
5. Rectum – Fissure – burning during stool
6. Generalities – Warmth – ameliorates
7. Skin – Eruptions – mucous membranes

Remedies coming through: *Arsenicum album, Bell, Lachesis, Graphites*

Final Choice: *Arsenicum album* (comprehensive coverage + constitutional similarity)

| Remedies | ars. | bell. | lach. | mur-ac. | rhus-t. | bry. | con. | graph. | sec. | sil. | ant-c. | chin. | crot-h. | hyos. | nit-ac. | ran-b. | sep. | spig. |
|-----------------------------|------|-------|-------|---------|---------|------|------|--------|------|------|--------|-------|---------|-------|---------|--------|------|-------|
| Serial Number | 1 | 2 | 3 | 4 | 5 | 6 | 7 | 8 | 9 | 10 | 11 | 12 | 13 | 14 | 15 | 16 | 17 | 18 |
| Symptoms Covered | 2 | 2 | 2 | 2 | 2 | 2 | 2 | 2 | 2 | 2 | 2 | 2 | 2 | 2 | 2 | 2 | 2 | 2 |
| Intensity | 4 | 4 | 4 | 4 | 4 | 3 | 3 | 3 | 3 | 3 | 2 | 2 | 2 | 2 | 2 | 2 | 2 | 2 |
| Result | 2/4 | 2/4 | 2/4 | 2/4 | 2/4 | 2/3 | 2/3 | 2/3 | 2/3 | 2/3 | 2/2 | 2/2 | 2/2 | 2/2 | 2/2 | 2/2 | 2/2 | 2/2 |
| Clipboard 6 | | | | | | | | | | | | | | | | | | |
| MIND - FORGETFUL | 1 | 2 | 2 | 3 | 2 | 1 | 2 | 2 | 1 | 1 | 1 | 1 | 1 | 1 | 1 | 1 | 1 | 1 |
| SKIN - ERUPTIONS - blackish | 3 | 2 | 2 | 1 | 2 | 2 | 1 | 1 | 2 | 2 | 1 | 1 | 1 | 1 | 1 | 1 | 1 | 1 |

XVII. Result and Follow-Up

- **Oral lesions:** Healed >90%, no new eruptions
- **Burning sensation:** Substantially reduced
- **Fissure:** Completely healed
- **Thyroid:** Improved clinically and biochemically
- **Mental health:** Reduced anxiety, better sleep and confidence

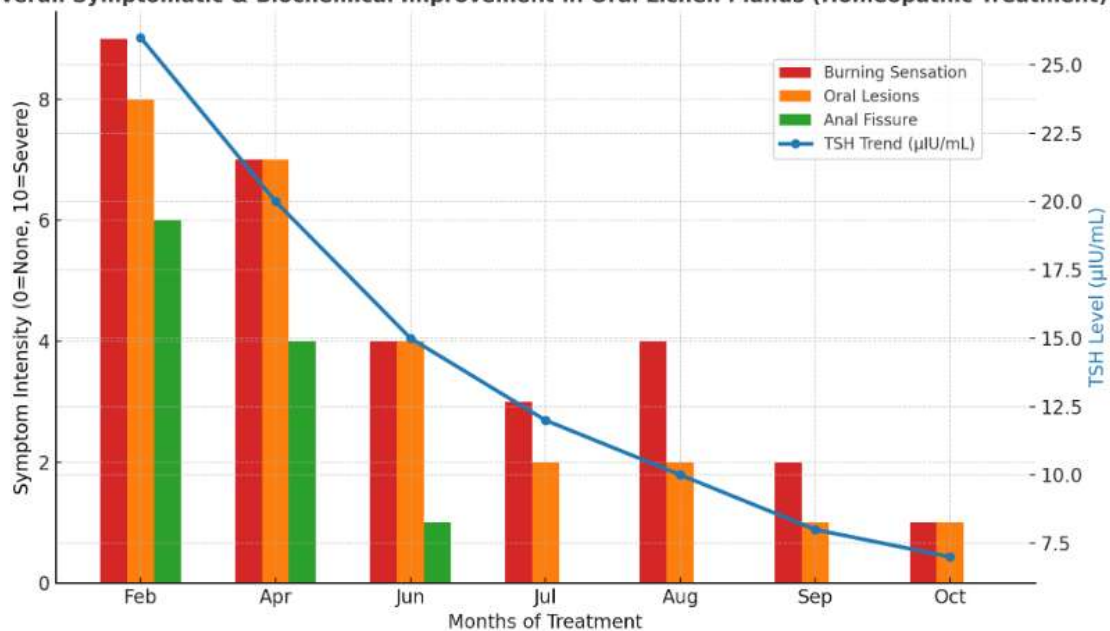
XVIII. Summary Table

| Parameter | Baseline | 3 Months | 6 Months |
|------------------|----------------|-----------------|----------|
| Burning in mouth | Severe (9/10) | 4/10 | 1/10 |
| Oral lesions | Extensive | Localized | Healed |
| Fissure pain | Present | Mild | Absent |
| TSH | 26 μ IU/mL | ↓ significantly | Stable |
| Energy level | Low | Better | Normal |
| Mental state | Anxious | Calm | Balanced |

XIX. Miasmatic Evolution (Before → After)

| Phase | Dominant Miasm | Clinical Manifestation |
|---------------|-----------------------|--|
| Initial | Psoro-syphilitic | Ulcerative OLP, anxiety, fissure |
| Mid-treatment | Psoric | Healing stage, reduced lesions |
| Final | Psoro-sycotic balance | Stable remission, normal thyroid trend |

Overall Symptomatic & Biochemical Improvement in Oral Lichen Planus (Homeopathic Treatment)



XX. Conclusion

This case illustrates a **classical totality-based approach** wherein *Arsenicum album* and *Sulphur* worked synergistically to correct both **local mucocutaneous pathology** and **systemic autoimmunity** (hypothyroid trend). The gradual miasmatic evolution from a destructive (syphilitic) to balanced (psoric-sycotic) phase supports the curative direction of treatment.

Homeopathy, when applied constitutionally, not only relieved symptoms but also restored systemic equilibrium and emotional stability — validating its deep-acting therapeutic scope in chronic autoimmune mucosal disorders like Oral Lichen Planus.