

Original Research Article

Volume 15 Issue 05

May 2026

## HOLISTIC HOMEOPATHIC ANALYSIS OF A CASE OF CHRONIC ORAL LICHEN PLANUS

**Dr Shireen Sayed**

Designation - CHC cum Mentor, Branch name, - Malleswaram

Dr Batra's Positive Health Clinic Pvt. Ltd., Qualification-MD,Trichologist

Email id- [drshireen.sayed@drbatras.com](mailto:drshireen.sayed@drbatras.com), Mobile-9986358482

### I. Case Identification

- **Patient:** Male, 41 years
- **Residence:** Bangalore (originally from Rajasthan)
- **Occupation:** Stationery shop salesman
- **Duration of complaints:** Oral lichen planus – 2 years; hypothyroidism – 2 years; anal fissure – 6 months
- **Date of first consultation:** 26 February 2025

### II. Presenting Complaints

1. **Burning pain in mouth**, < spicy or sour food
2. **Pricking sensation** in buccal mucosa
3. **Oral mucosal patches**, whitish-blackish discoloration, left buccal mucosa predominant
4. **Anal fissure** – burning and pain during defecation (earlier)
5. **Dryness of mouth**, occasional sensitivity
6. **No relief from steroids**, hence seeking alternative treatment

### III. Associated Complaints

- **Catarrhal irritation in eyes** with mucous discharge

- **Hypothyroidism** (TSH 26  $\mu$ IU/mL) with lethargy and mild weight gain
- **Forgetfulness**, absent-mindedness
- **Occasional mild anxiety and restlessness**

#### IV. Past History

- Took **steroids** earlier → temporary relief → relapse
- History of mild **hookah smoking** (stopped 4–5 years ago)

#### V. Family History

- **Father:** Hypertension, diabetes mellitus
- **Mother:** Suicide when patient was 3 years old (strong emotional imprint)
- **Step-mother:** Strained emotional background
- **No hereditary skin or autoimmune disorder**

#### VI. Personal History

- **Diet:** Vegetarian, Jain
- **Appetite:** Normal
- **Thirst:** 1–2 litres/day
- **Sleep:** Sound
- **Bowels:** Regular
- **Urine:** Normal
- **Physical activity:** Sedentary
- **Habits:** Hookah (past), no alcohol/tobacco now

#### VII. Mental Generals

- **Core emotion:** Anxiety with deep-seated insecurity
- **Personality:** Responsible, fastidious, sensitive, seeks reassurance
- **Stressors:** Financial worries, family duties, early childhood deprivation
- **Behavioral traits:**
  - Anxious about health, money, and family

- Tendency to brood over disappointments
- Fear of disease aggravation
- Easily fatigued mentally
- **Memory:** Forgetful, absent-minded (mental dullness post-thyroid dysfunction)
- **Temperament:** Mild, anxious, reserved; worries about future and responsibilities
- **Reaction to stress:** Internalizes emotions → psychosomatic flare-up

### VIII. Physical Generals

Parameter	Observation
<b>Thermal state</b>	Chilly, desires warmth
<b>Appetite</b>	Adequate
<b>Thirst</b>	Moderate
<b>Sleep</b>	Sound
<b>Perspiration</b>	Normal
<b>Desires</b>	Warm food, mild spice
<b>Aversions</b>	Spicy, sour foods (due to aggravation)
<b>Aggravations</b>	Spices, sour food, emotional stress, summer heat
<b>Ameliorations</b>	Warmth, bland food, rest, reassurance

### IX. Particulars

Particular	Description
<b>Mouth</b>	Burning, raw sensation, < spicy/sour; blackish patches left buccal mucosa
<b>Rectum</b>	Anal fissure, burning and pain during stool; better now
<b>Skin</b>	No eruptions elsewhere, mild itching around oral lesions
<b>Thyroid</b>	Hypothyroid trend, improved clinically with homeopathic medication
<b>Eyes</b>	Catarrhal discharge, mild irritation

### X. Causation (Etiology)

- **Emotional suppression and stress** from childhood trauma and current financial worries
- **Autoimmune tendency** (Hypothyroidism + Oral LP)
- **Suppressed eruptions** or iatrogenic suppression by corticosteroids

### XI. Diagnosis (Clinical)

- **Oral Lichen Planus (OLP)**
- **Hypothyroidism (Autoimmune – Hashimoto trend likely)**
- **Anal fissure secondary to constipation**

### XII. Miasmatic Analysis

Level	Evidence
<b>Psoric</b>	Hypersensitivity to stress, dryness, fissures, itching, anxiety, craving for warmth
<b>Syphilitic</b>	Destructive pathology of oral mucosa, ulceration, discoloration
<b>Syco-Psoric</b>	Hypothyroidism (endocrine sluggishness), infiltration of mucosa
<b>Dominant miasm:</b>	<b>Psoro-syphilitic</b> , with latent sycotic tendencies

### XIII. Totality of Symptoms

1. Anxiety about health, family, and finances
2. Forgetfulness, dullness of memory
3. Burning pain in mouth < spicy/sour food
4. Blackish, ulcerated mucosal lesions (left buccal mucosa)
5. Fissure in anus, burning during stool (earlier)
6. Catarrhal discharge from eyes
7. Hypothyroidism with sluggishness
8. Chilly patient, desires warmth
9. < Summer; > Warmth, bland diet
10. History of grief and early emotional loss

#### **XIV. Remedy Analysis**

##### **Remedy 1: Arsenicum album (*Constitutional + Acute*)**

###### **Key Correspondences:**

- Anxiety with insecurity about health and finances
- Burning pains relieved by warmth
- Fastidious, neat, cautious, sensitive to disorder
- Blackish discolorations of mucous membranes
- Hypersensitivity of oral mucosa, < spicy food
- Restlessness, anxious yet exhausted
- Suits chilly, debilitated constitutions

###### **Confirmatory Symptoms:**

- Mental restlessness with meticulous habits
- Burning pains > warmth
- Complaints after grief, loss, or financial worries

Hence, *Arsenicum album 200C* prescribed as **constitutional** and **acute** phase remedy.

##### **Remedy 2: Sulphur (*Intercurrent*)**

###### **Rationale:**

To clear psoric miasmatic blocks and sustain improvement in chronic mucosal inflammation.

###### **Key Traits:**

- Chronic tendency to mucocutaneous eruptions
- Heat, dryness, burning in mouth and anus
- Intellectual but forgetful, careless in habits
- Used as a complementary to *Arsenicum album* to balance psoric depth

Given as **200C**, fortnightly, intercurrent remedy.

**XV. Course of Treatment**

<b>Date</b>	<b>Observation</b>	<b>Remedy Given</b>
26 Feb 2025	Burning mouth, fissure pain; anxious	<i>Ars. alb</i> 200C daily x 15 days
01 Apr 2025	Burning reduced; fissure healing	Continued <i>Ars. alb</i> weekly
26 Apr 2025	Temporary aggravation	Diet correction, same remedy
09 Jun 2025	Stable, no new lesions, thyroid better	Added <i>Sulphur</i> 200C intercurrent
03 Jul 2025	Improved, no new lesions	Continued <i>Sulphur</i> fortnightly
01 Aug 2025	Mild aggravation while chewing	<i>Ars. alb</i> single dose
06 Sep 2025	Feels better, fissure healed	Maintain same
01 Oct 2025	Stable remission	Continued observation

**XVI. Repertorial Highlights****Rubrics Considered:**

1. Mind – Anxiety – health, about
2. Mind – Forgetfulness
3. Mouth – Pain – burning – food, spicy, from
4. Mouth – Discoloration – blackish
5. Rectum – Fissure – burning during stool
6. Generalities – Warmth – ameliorates
7. Skin – Eruptions – mucous membranes

**Remedies coming through:** *Arsenicum album, Bell, Lachesis, Graphites*

**Final Choice:** *Arsenicum album* (comprehensive coverage + constitutional similarity)

Remedies	ars.	bell.	lach.	mur-ac.	rhus-t.	bry.	con.	graph.	sec.	sil.	ant-c.	chin.	crot-h.	hyos.	nit-ac.	ran-b.	sep.	spig.
Serial Number	1	2	3	4	5	6	7	8	9	10	11	12	13	14	15	16	17	18
Symptoms Covered	2	2	2	2	2	2	2	2	2	2	2	2	2	2	2	2	2	2
Intensity	4	4	4	4	4	3	3	3	3	3	2	2	2	2	2	2	2	2
Result	2/4	2/4	2/4	2/4	2/4	2/3	2/3	2/3	2/3	2/3	2/2	2/2	2/2	2/2	2/2	2/2	2/2	2/2
Clipboard 6																		
MIND - FORGETFUL	1	2	2	3	2	1	2	2	1	1	1	1	1	1	1	1	1	1
SKIN - ERUPTIONS - blackish	3	2	2	1	2	2	1	1	2	2	1	1	1	1	1	1	1	1

**XVII. Result and Follow-Up**

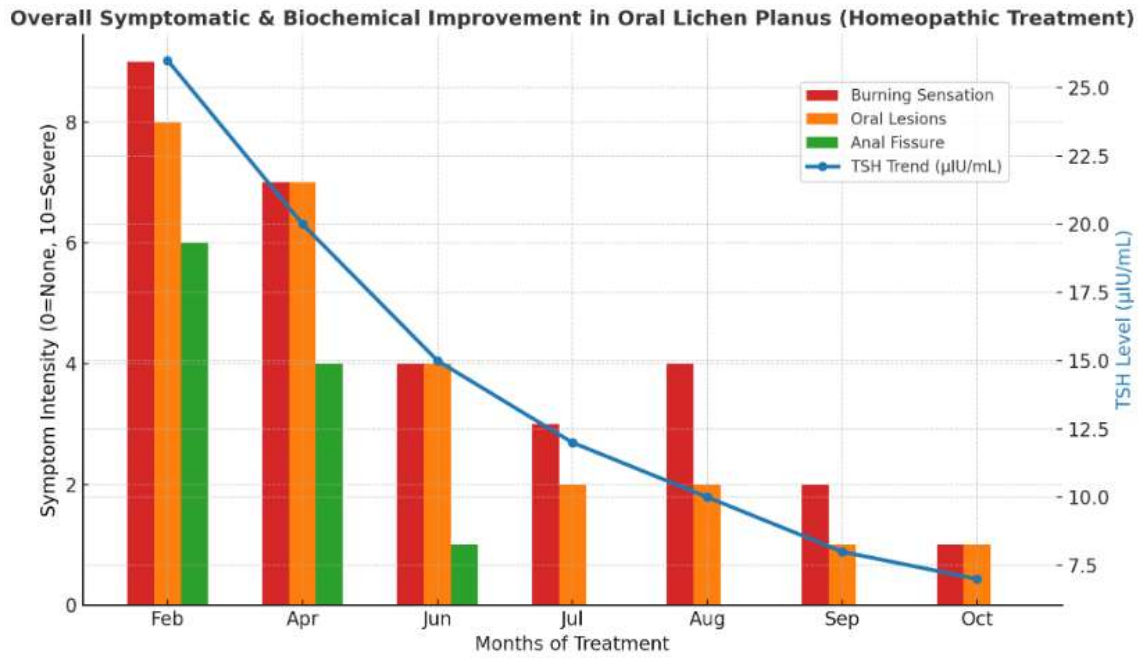
- **Oral lesions:** Healed >90%, no new eruptions
- **Burning sensation:** Substantially reduced
- **Fissure:** Completely healed
- **Thyroid:** Improved clinically and biochemically
- **Mental health:** Reduced anxiety, better sleep and confidence

**XVIII. Summary Table**

Parameter	Baseline	3 Months	6 Months
Burning in mouth	Severe (9/10)	4/10	1/10
Oral lesions	Extensive	Localized	Healed
Fissure pain	Present	Mild	Absent
TSH	26 µIU/mL	↓ significantly	Stable
Energy level	Low	Better	Normal
Mental state	Anxious	Calm	Balanced

**XIX. Miasmatic Evolution (Before → After)**

Phase	Dominant Miasm	Clinical Manifestation
Initial	Psoro-syphilitic	Ulcerative OLP, anxiety, fissure
Mid-treatment	Psoric	Healing stage, reduced lesions
Final	Psoro-sycotic balance	Stable remission, normal thyroid trend



## XX. Conclusion

This case illustrates a **classical totality-based approach** wherein *Arsenicum album* and *Sulphur* worked synergistically to correct both **local mucocutaneous pathology** and **systemic autoimmunity** (hypothyroid trend). The gradual miasmatic evolution from a destructive (syphilitic) to balanced (psoric-sycotic) phase supports the curative direction of treatment.

Homeopathy, when applied constitutionally, not only relieved symptoms but also restored systemic equilibrium and emotional stability — validating its deep-acting therapeutic scope in chronic autoimmune mucosal disorders like Oral Lichen Planus.