

Original Research Article

Volume 15 Issue 03

March 2026

DOI: <https://doi.org/10.5281/zenodo.19245458>

## INDIVIDUALIZED HOMOEOPATHIC TREATMENT OF PSORIASIS: A CASE REPORT

\*Dr. Vishal V Deshpande<sup>1</sup> and Dr. Jupudi Lakshmi Anupama<sup>2</sup>

*Prof. & HOD, Department of Case taking and Repertory, JIMS Homoeopathic Medical College and Hospital, Hyderabad, Telangana, India.*

[drvishalvd@gmail.com](mailto:drvishalvd@gmail.com) , 9422638599

*PG Scholar, part – II, Department of Case taking and Repertory, JIMS Homoeopathic Medical College and Hospital, Hyderabad, Telangana, India.*

[jlakshmianupama@gmail.com](mailto:jlakshmianupama@gmail.com), 8639034512

\*Corresponding Author's Email ID: [drvishalvd@gmail.com](mailto:drvishalvd@gmail.com)

### ABSTRACT

#### Background:

Psoriasis is a chronic immune-mediated inflammatory skin disorder characterized by erythema, induration, and silvery-white scaling, with a relapsing course and significant psychosomatic influence [1]. Conventional therapy often provides symptomatic relief but not long-term cure [2]. Homoeopathy considers skin disease to be an external expression of internal dysregulation, requiring individualized constitutional treatment [3]. **Case:** A 41-year-old man with a 2-year history of chronic plaque psoriasis affecting the scalp, trunk, and extremities presented with pruritus and scaling, which worsened following emotional distress after his father's suicide. The initial PASI score was 17.4, indicating moderate disease severity. An individualized homoeopathic approach using detailed evaluation of mental generals, emotional stressors, physical symptoms, and miasmatic background, remedies such as *Aurum muriaticum* and *Natrum muriaticum* resulted in marked clinical improvement, with the PASI score reducing to approximately 2. This case demonstrates the effectiveness of individualized homoeopathic management and supports the use of PASI as a reliable tool for assessing therapeutic outcomes.

**KEYWORDS:** Psoriasis, Homoeopathy, PASI, Chronic Skin Disease, Emotional Trauma, Similimum.

## **INTRODUCTION**

Psoriasis is a chronic inflammatory skin disease characterized by well demarcated erythematous, raised plaques with silvery white scales mainly affecting the skin and joints and its clinical course is characterized by remissions and exacerbations. It is characterised by well-defined, erythematous scaly plaques, particularly affecting extensor surfaces, scalp and nails, and usually follows a relapsing and remitting course. It can affect any age but mostly affect individuals between 11 to 60 years. It affects millions of people worldwide, with significant physical, psychological, and social burdens. Over the years, psoriasis has evolved from being viewed as a mere dermatological condition to being recognized as a systemic disease with potential comorbidities such as psoriatic arthritis, cardiovascular disease, and metabolic syndrome [4,5].

In homoeopathy, skin disease is viewed as an external manifestation of internal derangement of the vital force. The remedy must be selected based on whole totality considering the mental state, physical generals, and characteristic particulars. Failure to identify the similitum may lead to only temporary relief, stagnation, or aggravation of symptoms, as cautioned by Dr. Hahnemann, Dr. Kent, and Dr. Boenninghausen.

This case illustrates long-term management of psoriasis using individualized homoeopathic prescriptions guided by repertorial analysis and assessed objectively through the Psoriasis Area and Severity Index (PASI) [5].

## **MATERIAL AND METHOD**

A 41-year-old male patient presented to the outpatient department of JIMS Homeopathy Medical College & Hospital, Located in Shamshabad, Telangana, on 17 December 2022 with chronic psoriatic eruptions over duration of 2 years.

PASI scoring was applied to determine baseline severity and evaluate disease progression throughout follow-ups.

## **CASE**

The patient developed gradually spreading scaly eruptions over two years, initially appearing on the scalp and later spreading downwards to the ears, trunk, upper and lower limbs. Eruptions are dry, white, scaly eruptions have mild itching which are aggravated in winter season. No bleeding or pus

## **Past History**

Patient had history of dengue in 2014 for which he took allopathic treatment and recovered. He also had tonsillitis for which tonsillectomy done. Patient has medical history of chief complaint i.e. psoriasis only for which he received both allopathy and ayurveda which did not give him relief.

### **Family History**

- His father had myocardial infarction but later died by doing suicide [i.e. hanging]. His mother is having osteoarthritis for which she is taking medication

### **Physical Generals**

- He had profuse perspiration on exertion on whole body, desires sour food, & all other physical generals are normal, patient is thermally hot.

### **Mental Generals**

- He don't mixes very easily with people, prefers being alone and avoid social conflicts, speaks less, tends to internalize emotions rather than expressing them openly. He had a strong desire for music, which gave emotional ease and mental rest. His complaints got aggravated after his father's death by suicide i.e. hanging. He feels guilty after this incident by thinking that he had not done anything to save his father. He has absorbed in the thoughts of his father's death along with unhappiness & loneliness.

### **Clinical Findings**

- On clinical examination the patient pulse rate is 78bpm, his body temperature was recorded as 98.6-degree Fahrenheit, and his blood pressure was 110/80 mmhg.
- Dermatological examination revealed dryness of skin ++. Scaly eruptions which are turned blackish in colour has discharge on abdomen area.

### **Diagnosis: *Chronic Plaque Psoriasis***

Differentials considered: Eczema, Seborrhoeic dermatitis, Lichen planus.

### **Baseline PASI: 17.4 (Moderate Psoriasis)**

### **REPERTORIAL TOTALITY**

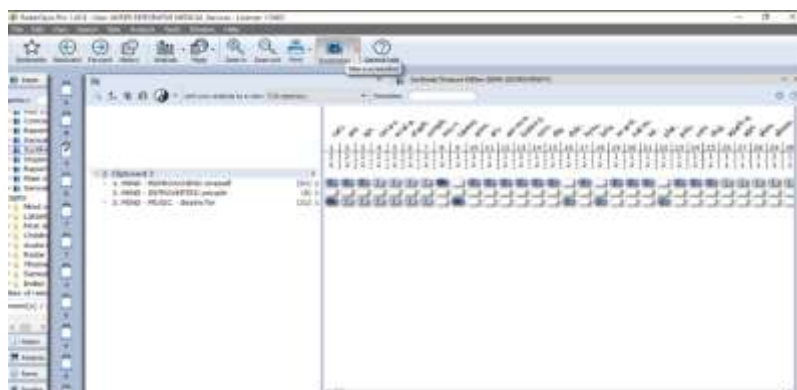
Mind – Guilt sense of

Mind – Introverted

Mind – music – desire for

## REPERTORIAL INTERFACE

Repertorization was conducted using Synthesis Repertory in Radar software.



**FIG.1** REPERTORIAL SHEET

## INTERVENTION

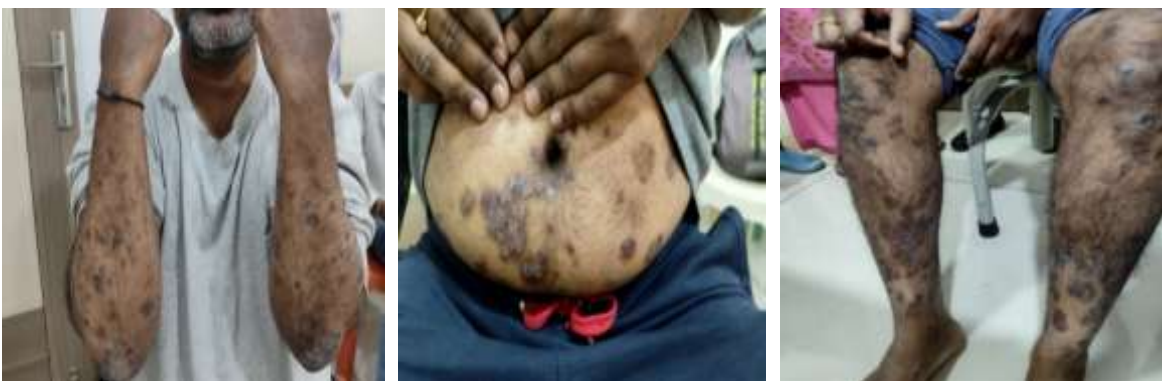After repertorization we got Aurum Met as a remedy, after closer differentiation Aurum Mur is selected based on unhappiness & loneliness after father's death & thermally hot patient. *Aurum muriaticum* 200, one dose was given as a 1<sup>st</sup> prescription and Rubrum BD for 21 days.

**TABLE 1: FOLLOW-UP AND OUTCOME**

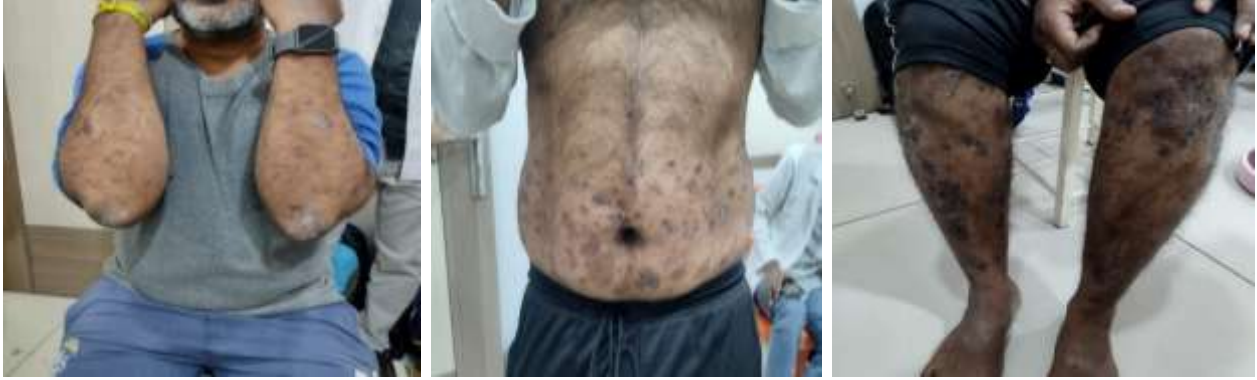Date	Changes in Symptomatology	PASI SCORE	Prescription
04-1-2023	Mild discharge with itching from eruptions & eruptions spread to other areas.	18.0	Rubrum 30/ BD/ 21 days
1-2-2023 to 1-11-2023	Patient is feeling better, eruptions and scaling is reducing and matching with skin colour. Itching is also reduced by 50%	14.5 - 8.5	Rubrum 30/ BD/ 21 days
13- 12-2023	Appearance Of New Lesions Over Arms In the last 2 Weeks	10.0	Aurum mur 200 1 dose Rubrum 30/ BD/ 21 days
07-06-2024	No itching/scaling; no new eruptions. Eruptions reduced all over the body.	3.0	Rubrum 30/ BD/ 21 days
04-09- 2024	Scaling only of old lesions; no itching & burning	3.5	Aurum mur 200

			Rubrum 30/ BD/ 21 days
20-11-2024	New Eruptions appeared on Hands and Legs and they are increasing in Size with scaling.No Itching; Burning; Case was reviewed as patient has improved Significantly up to certain level but now improvement Is Status Q. Totality considered: Grief, Introverted, helplessness Feeling of, Generous too much	6.5	Nat Mur 200 Rubrum 30/ BD/ 21 days
20-01-2025 to 20-02-2025	Eruptions reduced by 50%. No itching & scaling. No new eruptions	4.0 – 3.0	Rubrum 30/ BD/ 21 days
12-03-2025 to 23-04-2025	No new eruptions. Eruptions reduced to 60% Eruptions started to disappear and slowly changing in to skin colour. No itching; no burning	2.8 – 2.3	Rubrum 30/ BD/ 21 days
02-07-2025	No new eruptions; scaling++	2.5	Nat mur 1M Rubrum 30/ BD/ 21 days
17-10-2025	Eruptions reduced by 80%; no itching, scaling of eruptions.	2.0	Nat mur 1M Rubrum 30/ BD/ 21 days

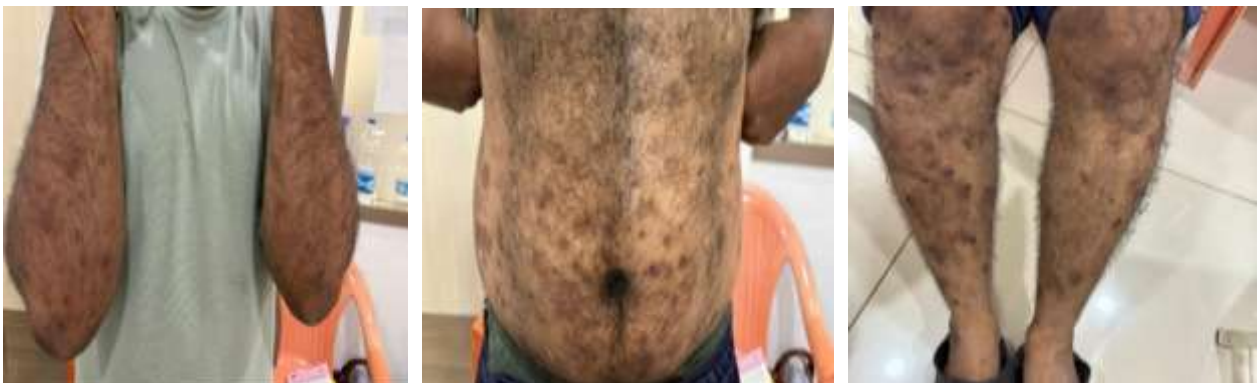### PHOTOGRAPHIC ILLUSTRATION AS EVIDENCE BASED RESULTS



**Before treatment [ 17/12/22]**



**During treatment [ 8/1/25]**



**After treatment [ 17/10/25]**

## **DISCUSSION**

In this case, Aurum muriaticum was initially prescribed based on the presenting totality of symptoms, which resulted in significant improvement. Subsequently, Natrum muriaticum was prescribed according to the changed totality, leading to complete recovery. This case highlights that achieving complete relief for the patient depends not only on the accuracy of the first prescription but also on the appropriateness of subsequent prescriptions based on the evolving totality of symptoms.

Initially, the patient predominantly experienced intense guilt regarding his father's death, which guided the prescription of Aurum muriaticum. Upon further review, the patient expressed feelings of helplessness during the time of his father's death, along with profound grief. This subtle yet significant change in the mental state indicated a shift in the remedy [9,10]. The case emphasizes that even a slight change in the patient's mental and emotional state can alter the indicated remedy, and as physicians, we must remain receptive and attentive to such changes.

In this case, the PASI score was initially 18, which improved to 2.0. The PASI score provided an objective framework to assess clinical progress and validated the gradual and consistent improvement achieved through homoeopathic treatment [5].

## CONCLUSION

This case highlights the role of the similimum selected through complete totality mental, emotional, and physician achieving long-lasting improvement in psoriasis. PASI served as an effective tool for monitoring long-term outcomes. Individualized homoeopathic treatment may offer significant benefit in chronic dermatological disorders with psychosomatic components.

## CONFLICT OF INTEREST

Not available

## FINANCIAL SUPPORT

Not available

## DECLARATION OF PATIENT CONSENT

Patient consent was taken for images to be reported for this article.

## REFERENCE

1. Khanna N. *Illustrated synopsis of dermatology and sexually transmitted diseases*. 5th ed. New Delhi: Elsevier; 2015.
2. Coondoo A, Phiske M, Verma S, Lahiri K. Side-effects of topical steroids: a long overdue revisit. *Indian Dermatol Online J*. 2014;5(4):416–425. Available from: <https://www.ncbi.nlm.nih.gov/pmc/articles/PMC4228634/> doi:10.4103/2229-5178.142483
3. Sharma A, et al. Sequel of dermatological suppression. *Int J Homoeopath Sci*. 2022;6(2):286–288. Available from: <https://www.homoeopathicjournal.com/articles/572/6-2-31-795.pdf> doi:10.33545/26164485.2022.v6.i2e.572
4. Saavedra AP, Roh EK, Mikailov A, Wolff K. *Fitzpatrick's color atlas and synopsis of clinical dermatology*. 9th ed. New York: McGraw Hill; 2023.

5. Coimbra S, et al. Psoriasis: epidemiology, clinical and histological features, triggering factors, assessment of severity and psychosocial aspects. In: InTech; 2012. Available from: <https://doi.org/10.5772/26474>
6. Hahnemann S. *Organon of medicine*. 6th ed. New Delhi: B Jain Publishers; 1994.
7. Kent JT. *Lectures on homoeopathic philosophy*. New Delhi: B Jain Publishers; 2002.
8. Bönninghausen CV. *Therapeutic pocket book*. New Delhi: B Jain Publishers; 2004.
9. Murphy R. *Lotus materia medica*. New Delhi: B Jain Publishers Pvt Ltd; 2021.
10. Sankaran R. *The spirit of homoeopathy*. Mumbai: Homoeopathic Medical Publishers; 2001.