

Original Research Article

Volume 15 Issue 02

February 2026

**LONG-STANDING CHRONIC RHINOSINUSITIS WITH NASAL POLYPOSIS
SUCCESSFULLY MANAGED WITH INDIVIDUALIZED CLASSICAL
HOMEOPATHY AT DR BATRA'S® HOMEOPATHY CLINIC – A CASE REPORT**

Dr Ashwini Ujawe

Chief Homeopathic Consultant

Lokhandwala Branch

Dr Batra's Positive Health Clinic Pvt. Ltd.

Qualification BHMS

Email id chc-lokhandwala@drbatras.com, Mobile: 816 971 4197

Abstract

Chronic rhinosinusitis with nasal polyposis is a persistent inflammatory disorder often requiring long-term medication or surgical intervention, with frequent relapses. This case report presents a 52-year-old male with a history of nasal obstruction spanning over three decades, associated with sinus involvement confirmed radiologically, who showed poor long-term response to conventional management. A classical individualized homeopathic approach was adopted based on detailed life-space exploration, mental generals evolving from childhood, physical generals, and totality of symptoms. Significant and sustained clinical improvement with long-term remission was achieved, highlighting a clear transformation under homeopathic treatment at **Dr Batra's® Homeopathy Clinic**.

Keywords

Chronic sinusitis, nasal polyposis, classical homeopathy, individualized medicine, miasmatic approach, Dr Batra's Homeopathy Clinic

Introduction

Chronic rhinosinusitis (CRS), particularly when associated with nasal polyps, is a complex inflammatory condition characterized by nasal obstruction, mucosal edema, sinus congestion, and impaired quality of life. Conventional management often involves prolonged use of intranasal steroids, antihistamines, and repeated courses of antibiotics, with surgery reserved for refractory cases. Despite this, recurrence remains common.

Homeopathy, with its individualized constitutional approach, aims to treat not merely the local pathology but the patient as a whole—addressing mental, emotional, and physical dimensions. This case illustrates the successful management of long-standing CRS with nasal polyposis through classical homeopathy, emphasizing constitutional prescribing, miasmatic understanding, and long-term follow-up.

Case Profile

- **Age / Gender:** 52 years / Male
- **Occupation:** Marketing & Sales (Field work)
- **Marital Status:** Married, living with wife and daughter
- **Clinical Setting:** Dr Batra's® Homeopathy Clinic
- **Diagnosis:** Chronic Rhinosinusitis with Nasal Polyposis
- **Duration of Illness:** ~30–35 years (active complaints for last 1 year prior to consultation)

Chief Complaints

- Persistent nasal blockage, alternating but predominantly left-sided
- Sensation of congestion without significant discharge
- Aggravation at night and in lying-down position
- Long-standing mouth breathing
- Episodic sneezing and heaviness in head
- Reduced sense of smell (anosmia – on and off)

Investigations

CT Scan of Paranasal Sinuses (11 May 2023):

- Polypoidal mucosal thickening
- Involvement of sphenoid and right frontal sinus

- Obstruction of bilateral osteomeatal complexes
- Bilateral frontal and sphenoidal recess involvement

Past & Family History

- **Past History:** No major systemic illness
- **Family History:** Non-contributory for major chronic diseases; family tendency toward allergic conditions noted later during follow-up

Life Space & Mental Generals

The patient described a **stable and emotionally secure childhood**, growing up in a modest family environment. His father worked as a laborer and his mother was a homemaker. Academically, he performed above average and did not experience examination anxiety or competitive stress. There was no history of bullying or significant emotional trauma.

From early life, the patient demonstrated a **reserved and introverted disposition**, preferring limited social interaction. He reported being calm by nature, not easily angered, and generally adaptable to circumstances. Emotional expression was minimal; he tended to internalize feelings rather than share them openly, even with close family members.

As adulthood progressed, this emotional pattern remained consistent. He described himself as sincere, honest, hardworking, and family-oriented, with manageable work stress despite long years in marketing and field sales. He did not report marked fears, anxieties, or mood fluctuations but admitted to being **easily affected emotionally**, though without outward expression.

Decision-making was practical and swift, without excessive overthinking. Ambition was moderate, and life was approached with a “going with the flow” attitude. Overall, the mental picture reflected **emotional restraint, introversion, calmness, and stability**, with a tendency to suppress rather than express internal states.

Physical Generals

- **Thermal Reaction:** Ambithermal
- **Thirst:** 2–3 liters/day
- **Perspiration:** Profuse
- **Sleep:** 7–8 hours, refreshing
- **Appetite:** Normal
- **Cravings:** Spicy food
- **Aversions:** Sweets

- **Bowel Habits:** Satisfactory
- **Urine:** Normal

Totality of Symptoms

1. Chronic nasal obstruction for decades
2. Alternating sides, left predominance
3. Aggravation at night and lying down
4. Long-standing sinus pathology with polyps
5. Calm, introverted personality
6. Emotionally sensitive but reserved
7. Profuse perspiration
8. Desire for spicy food, aversion to sweets

Repertorial Analysis

Selected Rubrics

- Nose – Obstruction – chronic
- Nose – Obstruction – night
- Nose – Polyps
- Nose – Sinusitis
- Mind – Reserved
- Mind – Introverted
- Mind – Calmness
- Generals – Food – Spices – desire
- Generals – Perspiration – profuse

Repertorization Outcome:

Leading remedies: **Natrum muriaticum, Silicea, Pulsatilla**

Miasmatic Understanding

The case predominantly reflected a **syco-syphilitic miasm**, evident from:

- Long-standing chronicity
- Structural changes (polyps, mucosal thickening)

- Slow progression with periodic aggravations

Allergy Testing and Dietary Evaluation

Considering the chronicity of rhinosinusitis and its strong association with allergic triggers, an **allergy assessment** was performed to identify potential dietary and environmental contributors aggravating the inflammatory state.

Allergy Test Findings

The allergy test revealed differential reactivity to multiple food substances, which were categorized based on tolerance levels:

- **Consume Freely (Grade 0 – Non-reactive):**
Lentils (tur dal, chana dal, mung dal), peanuts, soybean, cocoa, chicken, lamb, pork, fish (kingfish, mackerel), prawns, crab, shrimp, broccoli, carrot, potato, tomato, onion, brinjal, cabbage, banana, apple, black raisin, olive, black currant, strawberry, cow milk, egg, cucumber, ginger, garlic.
- **Observe (Grade 1 – Mild Reactivity):**
Gluten, flaxseed.
- **Reduce / Avoid (Grade 2 – Moderate Reactivity):**
Oats, wheat, rice, corn, semolina, barley, rye, almond, cashew, walnut, tea.

Clinical Interpretation

The presence of gluten and cereal-based food sensitivities indicated a **low-grade chronic inflammatory load**, potentially contributing to persistent nasal mucosal edema and sinus blockage. Long-term dietary exposure to these allergens may have acted as **maintaining causes**, perpetuating the disease process despite conventional treatment.

Integration with Homeopathic Management

Dietary regulation was advised alongside homeopathic treatment, focusing on:

- Reduction of identified allergenic foods
- Avoidance during periods of exacerbation
- Gradual reintroduction based on symptom response

Importantly, dietary modification was **supportive and not curative**, as the primary therapeutic goal remained constitutional correction through individualized homeopathic remedies. With progression of treatment, the patient demonstrated **reduced sensitivity to allergens**, reflected clinically by decreased frequency and intensity of nasal congestion and improved overall stability.

Natrum muriaticum was selected as the constitutional remedy, supported by intercurrent and acute prescriptions as required.

Prescription & Follow-Up Table

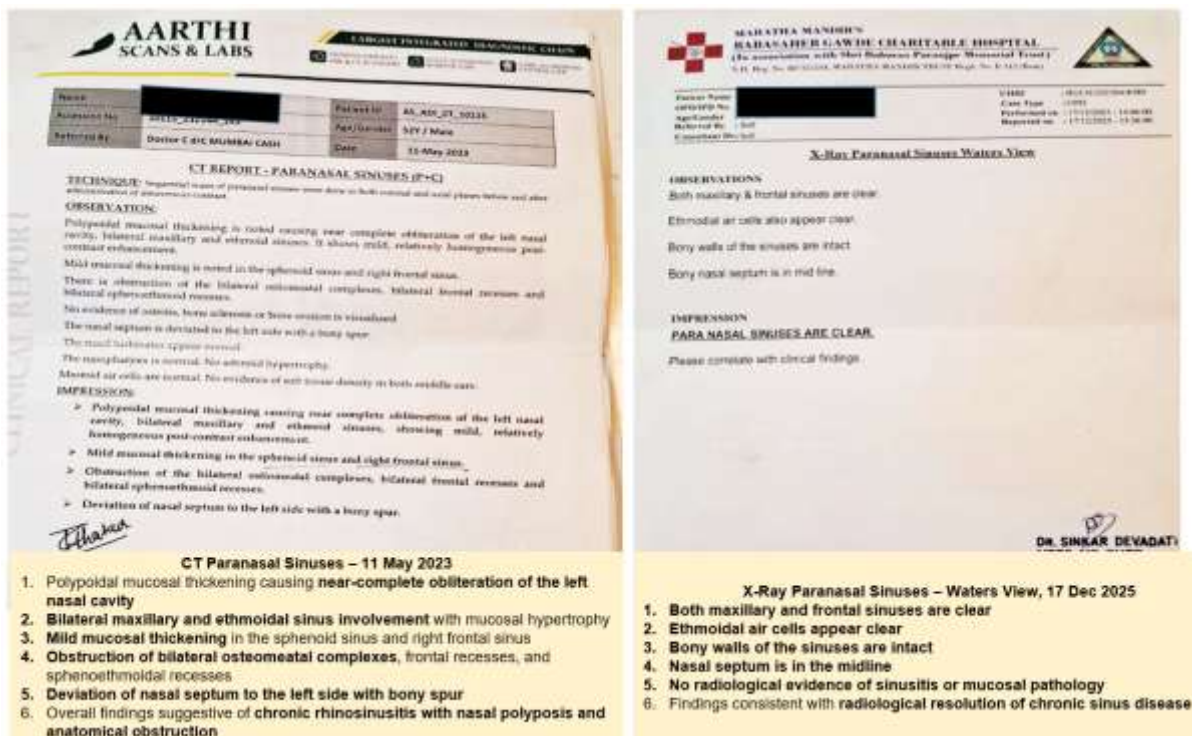
Date	Clinical Status	Remedy	Potency	Dose	Remarks
Initial	Severe nasal block, chronic sinusitis	Natrum muriaticum	200C	Single dose	Constitutional
Follow-up	Acute exacerbation	Sabadilla	200C	Short course	Acute phase
Follow-up	Stagnation with polyp tendency	Thuja	200C	Intercurrent	Anti-sycotic
Long-term	Gradual improvement	Natrum muriaticum	200C	Repeated as needed	Maintenance

Follow-Up Summary

- **3–6 months:** Reduction in nasal blockage frequency, improved sleep
- **6–12 months:** Reduced dependency on allopathic nasal sprays
- **1–2 years:** Significant decrease in congestion, improved breathing
- **>3 years:** Sustained remission, no acute spikes, clear chest, improved quality of life

Transformation Table

Parameter	Before Treatment	After Treatment
Nasal blockage	Daily, severe	Occasional, mild
Sinus congestion	Persistent	Minimal
Dependency on sprays	Daily	Nil
Sleep quality	Disturbed	Refreshing
Work efficiency	Affected	Restored
Quality of life	Compromised	Significantly improved



Discussion

This case highlights the effectiveness of individualized classical homeopathy in managing chronic rhinosinusitis with nasal polyposis. Despite decades of illness and structural sinus pathology, a well-selected constitutional remedy brought sustained improvement without surgical intervention. The patient’s mental and emotional profile played a crucial role in remedy selection, reinforcing the importance of life-space evaluation.

The gradual yet consistent response underscores the depth of action of constitutional remedies when prescribed based on totality and miasmatic understanding. Reduction and eventual cessation of conventional medication further demonstrate true curative response rather than symptomatic suppression. This case also emphasizes the importance of long-term follow-up in chronic cases to assess stability and prevent relapse.

Conclusion

This case demonstrates that chronic rhinosinusitis with nasal polyposis, even of long duration, can be effectively managed through individualized classical homeopathy. A holistic assessment incorporating mental, physical, and constitutional dimensions led to sustained clinical improvement and long-term remission. The transformation achieved under systematic homeopathic care at **Dr Batra’s® Homeopathy Clinic** reinforces homeopathy’s

role as a safe, effective, and integrative therapeutic option for chronic allergic and respiratory disorders.

References

1. Hahnemann S. *Organon of Medicine*. 6th ed.
2. Kent JT. *Lectures on Homoeopathic Philosophy*.
3. Boericke W. *Pocket Manual of Homoeopathic Materia Medica*.
4. Allen HC. *Keynotes and Characteristics*.
5. Clarke JH. *Dictionary of Practical Materia Medica*.
6. Davidson M. Chronic sinusitis: conventional challenges. *J Otolaryngol*.
7. Bellavite P, et al. Immunological effects of homeopathy. *Homeopathy*.
8. Sankaran R. *The Spirit of Homoeopathy*.
9. Vithoulkas G. *The Science of Homoeopathy*.
10. World Health Organization. Traditional medicine strategy.