



Original Research Article

Volume 14 Issue 11

November 2025

## CASE STUDY: SUCCESSFUL HOMEOPATHIC MANAGEMENT OF COMPLEX RIGHT OVARIAN CYST AVOIDING SURGERY

Dr Aruna Pathania

BHMS, CHC, Yamuna nagar Branch

Dr Batra's Positive Health Clinic Pvt. Ltd.

Email id [arunapathania1984@gmail.com](mailto:arunapathania1984@gmail.com), Mobile 8818007030

### Abstract

A 42-year-old female presented with a chronic right lower abdominal pain persisting for 4 months. Ultrasonography revealed a complex right ovarian cyst measuring 40×50 mm. The patient also had a long-standing history of infertility for 25 years, with four conceptions, each ending in miscarriage around the second month of gestation. Despite normal investigations including ovulatory studies and regular menstrual cycles, conception could not be sustained. She also experienced premenstrual mastalgia (breast pain 10 days before menses). The patient was advised surgical removal of the cyst by allopathic physicians, which caused significant anxiety and emotional distress. Opting for homeopathic management at Dr. Batra's clinic, she was prescribed **Natrum carbonicum 200C** based on totality of symptoms and constitutional analysis. Remarkable improvement was noted within 3 months — pain completely subsided, and subsequent ultrasonography showed **no significant abnormality detected**, confirming complete resolution of the ovarian cyst. The case demonstrates the efficacy of individualized homeopathic treatment in the successful non-surgical management of ovarian cysts and related gynecological issues.

### Keywords:

Ovarian cyst, Infertility, Natrum carbonicum, Homeopathy, Non-surgical management

## Introduction

Ovarian cysts are common gynecological disorders that often lead to pelvic pain, menstrual irregularities, and fertility issues. Conventional medicine frequently recommends surgical removal for large or complex cysts. However, homeopathy offers a safe, gentle, and non-invasive alternative by addressing the root cause and restoring hormonal and systemic balance. This case report highlights the successful treatment of a complex right ovarian cyst using **Natrum carbonicum 200C**, with complete regression of the cyst and avoidance of surgery.

## Case History

### Patient Profile:

- **Age/Sex:** 42-year-old female
- **Marital history:** Married for 25 years
- **Occupation:** Homemaker
- **Date of first consultation:** 16.08.2025

### Chief Complaint:

- Continuous pain in the right lower abdomen for the past 4 months.
- USG revealed a **complex right ovarian cyst measuring 40×50 mm**.

### Associated Complaints:

- Pain and tenderness in breasts, especially 10 days prior to menses.
- History of **infertility for 25 years** — conceived 4 times, all ending in miscarriage at approximately 2 months.

### Menstrual History:

- Regular cycles, moderate flow, without clots.
- No dysmenorrhea or intermenstrual bleeding.

### Past History:

- No major illnesses or surgeries.

## Family History:

- Non-contributory.

## Personal History:

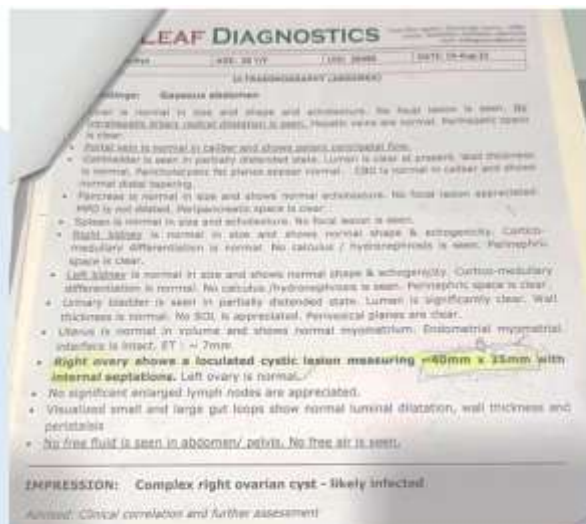
- Appetite: Moderate
- Thirst: Normal
- Cravings: Salty food
- Sleep: Sound
- Bowel/bladder: Regular

## Mind/Emotional Sphere:


- Extremely sensitive and emotional; often suppresses emotions.
- Anxiety about health and fertility.
- Reserved, does not share her feelings easily.
- Feels disappointment when hopes are not fulfilled.

## Clinical Findings

- **USG (August 2025):** Complex right ovarian cyst (40×50 mm), possibly infected.
- **USG (October 2025):** No significant abnormality detected.



16.08.25  
Complex right ovarian cyst : INFECTED



22.10.25  
No significant abnormality detected

## Diagnosis

- **Clinical Diagnosis:** Complex right ovarian cyst (infected).
- **Homeopathic Diagnosis:** Chronic ovarian affection with hormonal imbalance — Natrum carbonicum constitution.

## Remedy Selected

### Natrum carbonicum 200C

- **Justification for Remedy Selection:**
  - Suited to women with long-standing infertility and habitual miscarriages.
  - Tendency to weakness of reproductive organs.
  - Sensitive and reserved temperament.
  - Complaints aggravated before menses.
  - General weakness after exertion or emotional distress.

## Potency & Repetition:

- Natrum carbonicum 200C, one dose weekly, followed by placebo as required.

## Follow-Up and Outcome

Date	Findings / Progress
16.08.2025	Pain in right lower abdomen since 4 months; cyst 40×50 mm on USG; anxious about surgery.
22.09.2025	Pain reduced by 50%; improved sleep and emotional calmness.
22.10.2025	No abdominal pain; USG showed <i>no significant abnormality detected</i> .
16.11.2025	Stable condition; symptom-free; confidence regained.

## Discussion

This case demonstrates how individualized homeopathic management can effectively treat complex ovarian cysts and prevent unnecessary surgical intervention. Natrum carbonicum acted deeply on the hormonal and emotional axis, helping restore the patient's internal balance. The resolution of the cyst and disappearance of pain within three months reflect both the curative and preventive potential of homeopathy in gynecological pathology.

## Conclusion

Homeopathy offers a holistic, non-invasive alternative in managing complex ovarian cysts and associated infertility. This case confirms the potential of individualized remedy selection—particularly **Natrum carbonicum**—in achieving complete recovery without surgical procedures, emphasizing the importance of mind-body connection in chronic reproductive conditions.

## References

1. Boericke, W. *Pocket Manual of Homeopathic Materia Medica*.
2. Clarke, J.H. *A Dictionary of Practical Materia Medica*.
3. Allen, T.F. *The Encyclopedia of Pure Materia Medica*.
4. Kent, J.T. *Lectures on Homeopathic Materia Medica*.
5. Dr. Batra's Clinical Case Archives (2025).