

Original Research Article

Volume 14 Issue 09

September 2025

A NON-SURGICAL RESOLUTION OF CERVICAL GLAND SWELLING THROUGH CLASSICAL HOMEOPATHY

Dr Ambreen Fatima

Chief Homeopathic Consultant, Jabalpur Branch,

Dr Batra's Positive Health Clinic Pvt. Ltd.

Qualification BHMS

Email id chc-jabalpur@drbatras.com

Mobile 9752266956

Abstract

Lymphadenopathy is the abnormal enlargement of lymph nodes, commonly seen in infections, immune disorders, or malignancies. Cervical lymphadenopathy is a frequent clinical concern worldwide, especially in regions with high infectious disease prevalence. Homeopathy views lymphadenopathy as a reflection of internal imbalance rather than a localized issue. This paper presents a case of a 43-year-old female with a painless, gradually enlarging neck swelling, diagnosed as lymphadenopathy via FNAC. The case highlights the role of individualized homeopathic treatment in managing chronic glandular swellings at Dr Batra's.

Keywords: Lymphadenopathy, Neck swelling, Homeopathy, Dr Batra's

Introduction

Lymphadenopathy refers to the enlargement of lymph nodes, which may result from various etiologies including infections, autoimmune conditions, and malignancies [1]. It is one of the most common clinical signs encountered in both pediatric and adult populations [2]. Cervical lymphadenopathy, in particular, is often the result of upper respiratory tract infections, tuberculosis, viral illnesses, or neoplastic processes [3].

The affected lymph nodes may present as soft or firm, mobile or fixed, painful or painless, and single or multiple. The chronicity, location, and consistency of the nodes provide important diagnostic clues. In some cases, especially painless and progressively enlarging nodes, further evaluation with imaging and cytology, such as FNAC (Fine Needle Aspiration Cytology), is crucial to rule out sinister causes such as lymphoma or metastatic disease [4].

Complications can include abscess formation, fistula, pressure effects, or progression to malignancy if not addressed timely. In conventional medicine, the treatment largely depends on the underlying pathology, often involving antibiotics, anti-tubercular therapy, or surgical intervention when necessary.

In homeopathy, however, the focus is to stimulate the body's natural healing response by addressing the underlying susceptibility. Remedies are chosen based on the complete symptom picture, including mental and physical attributes, family history, and miasmatic tendencies. This case study aims to highlight how homeopathy can play a significant role in managing chronic lymphadenopathy without invasive procedures.

Case Profile

A 43-year-old female presented to the clinic in Jabalpur with a complaint of swelling in the neck region, persisting for the past four months. The swelling is located on the right side of the neck and measures approximately 2 cm in diameter. The patient reports no pain associated with the swelling; however, she has observed a gradual increase in its size over time. Fine Needle Aspiration Cytology (FNAC) was performed, and the impression was suggestive of lymphadenopathy. Further evaluation and individualized assessment are necessary to determine the underlying cause and plan appropriate treatment.

Physical Generals

Menses: Regular

Craving: Salt

Diet: Mixed

Appetite: Good

Desire: Salt

Aversion: Not marked

Thirst: Normal

Stools: Regular

Urine: Normal

Perspiration: Normal

Sleep: Refreshing

Dreams: Not significant

Thermals: Chilly

Local Examination:

- Swelling observed on the **right lateral side of the neck** (submandibular region)
- **Size:** Approximately **2 cm in diameter**
- **Shape & Surface:** Smooth, round, well-defined margins
- **Consistency:** Hard and cystic on palpation
- **Tenderness:** Slight tenderness only on deep or harsh pressure
- **Mobility:** Slightly movable, not fixed to deeper structures
- **Skin over swelling:** Normal in color and texture, no signs of inflammation or redness
- **No discharges** or ulceration observed
- **No associated lymph nodes** palpable in other regions

Mental Generals –

The patient is a 43-year-old housewife from a small village in Bihar, currently residing in Jabalpur due to her husband's transferable job in the army. She studied till class 12 and was married at the age of 21, in line with early marriage traditions common in her village. She has two sons aged 20 and 16 and lives a routine domestic life as a homemaker. During childhood, she enjoyed a friendly relationship with her four sisters and two brothers, had good relations with teachers, and performed reasonably well in school. No major emotional traumas were reported in her early life.

In adult life, however, she has become noticeably anxious, emotionally sensitive, and withdrawn. She describes herself as introverted, impatient, and highly religious, with limited social interaction and few friends. Her personality reflects deep-rooted superstition and a firm belief in black magic and evil spirits. She often expresses fixed thoughts such as, "Mujhe lagta hai koi saaya hai mere ghar mei," and tends to avoid strangers, feeling something unnatural has been done to her. These delusions are not easily shaken; even when her husband tries to explain rationally, she refuses to change her mind or trust his advice.

Her emotional responses include suppressed anger, especially in front of her in-laws or when her desires are denied (such as visiting her parents). Rather than voicing disagreement, she quietly obeys, though internally affected. She is highly anxious and mentally rigid, often worrying over minor issues, and does not have the confidence to take decisions independently. Her husband reports that she is a good listener but remains mentally fixed and difficult to persuade. She becomes very emotional and tends to cry in solitude over small matters, revealing an internal struggle between obedience and suppressed emotional needs.

Her belief in the supernatural has influenced her health choices as well. Initially, she resisted seeking medical care and instead attempted local spiritual remedies ("totka") believing the swelling in her neck was caused by some supernatural force. When she eventually visited a surgeon and was advised surgery, her fear and hesitation led her to refuse the procedure and opt for homeopathic treatment instead. The stress around the swelling has been a major emotional burden for her, amplifying her fears and reinforcing her belief in something being "done" to her. Despite this, her happiest moments remain centered around her children's births, and she finds comfort in cooking and watching television. Overall, her mental symptoms are characterized by superstition, fixed delusions, suspicion, emotional dependence, and anxiety, all of which heavily influence her perception of illness and treatment.

Past History

N.S

Family History

N.S

Case analysis Reportorial totality

Repertory used	Rubrics selected
Synthesis	<ul style="list-style-type: none"> – 1. I Ideas fixed – 2. EXTERNAL THROAT - SWELLING - Cervical Glands – 3. THROAT INTERNAL - CHOKING, constricting - daytime – 4. T Tonsils - enlarged – 5. T - Tonsils - red - bright – 6. MIND - COMPANY, aversion to avoids the sight of people – 7. MIND - COMPANY, - aversion to presence of strangers, to – 8. MIND - DELUSIONS, faces, sees - hideous – 9. MIND - DELUSIONS, - insane, that people think her

Repertory screenshot

		calc.	thu.	nat-s.	bell.	iod.	sep.	acon.	bar-c.	con.	
		1	2	3	4	5	6	7	8	9	10
		516	424	409	379	305	305	304	291	291	291
1. Clipboard 1											
▶ 1. I - Ideas - fixed	(9) 1		1								
▶ 2. EXTERNAL THROAT - SWELLING - Cervical Glands	(70) 1	3	2	2	3	2	2		3	2	3
▶ 3. THROAT INTERNAL - CHOKING,constricting - daytime	(1) 1			1							
▶ 4. T - Tonsils - enlarged	(16) 1								3	1	2
▶ 5. T - Tonsils - red - bright	(3) 1				2			1			
▶ 6. MIND - COMPANY, - aversion to - avoids the sight of people	(10) 1		2			2	2	1			
▶ 7. MIND - COMPANY, - aversion to - presence of strangers,to	(13) 1		2			2	2		2	2	1
▶ 8. MIND - DELUSIONS, - faces,sees - hideous	(13) 1	3			2						
▶ 9. MIND - DELUSIONS, - insane, - that people think her	(1) 1	3									

Selection of Remedy

Remedy Type	Remedy Name	Potency	Dose	Reasons
Constitutional	Thuja	1M	Single dose	Selected based on strong mental indications—fixed ideas, superstitious beliefs, suspicion, and fear of evil forces. As per §279 and footnote of §282 (6th edition of Organon), in chronic cases involving sycotic traits, a high potency is necessary to match the depth of the disease. Thuja also covers suppressed emotions, introversion, and delusions of being possessed or controlled.
Acute	Phytolacca	Mother Tincture	10–15 drops in water, TID	Chosen for its specific action on glandular swellings. The patient has a hard, smooth, painless cervical swelling with a sensation of something stuck in the throat, which is well covered by this remedy in its mother tincture form.

THUJA

Mind.—Fixed ideas; that a stranger is always at his side, that mind and body are separated. Vacancy in head, with inability to think. Slow speech, with frequent interruption, because he is

PHYTOLACCA

Mind.—Loss of personal delicacy. Indisposition to mental exertion. Indifference.

Throat.—Congested and dark red. Sore. Rough and dry, with aching in neck, back and limbs. Choking as from a lump, hot ball or apple-core lodged therein. Smarting or raw, scraped feeling in. Much hawking to clear it of increased mucus, with, no relief. Excruciating pains shoot through ears on attempting to swallow. Eruption in Worse: Hot drinks. Better: Liquids.

Stomach.—Intense thirst. Violent retching and vomiting; distress so intense, he desired death. Vomiting; with purging; (Anno): painless.

Miasmatic approach

Symptoms	Psora	Sycosis	Syphilis	Tub
1. Fixed ideas (rigid thinking, superstition)		✓		
2. Swelling of cervical glands (external throat)		✓		✓
3. Choking/constriction in throat, especially during daytime	✓	✓		
6. Aversion to company, avoids sight of people	✓			
7. Aversion to strangers	✓			

Materials and Methods

Synthesis repertory was used for repertorization

Results

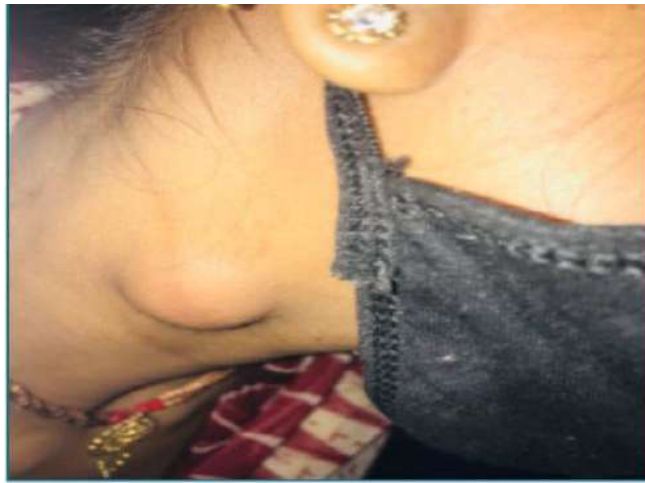
Month	Progress	Prescription
1st Month	Swelling slightly reduced in size; less sensation of choking; mentally calmer and more cooperative	Thuja 1M – 2 doses/week Apis Mellifica 200C – twice daily Calcarea Phos 6X – twice daily Phytolacca MT – 10 drops twice daily
2nd Month	Further reduction in gland size; no new symptoms; no choking or pressure feeling; emotionally more stable	Same as above continued with positive response; no change in prescription
3rd Month	Swelling minimal; mentally confident; overall condition stable and improved	Plan to taper doses gradually; continued Phytolacca MT and Calc-P 6X; single dose of Thuja 1M maintained

Discussion & Conclusion

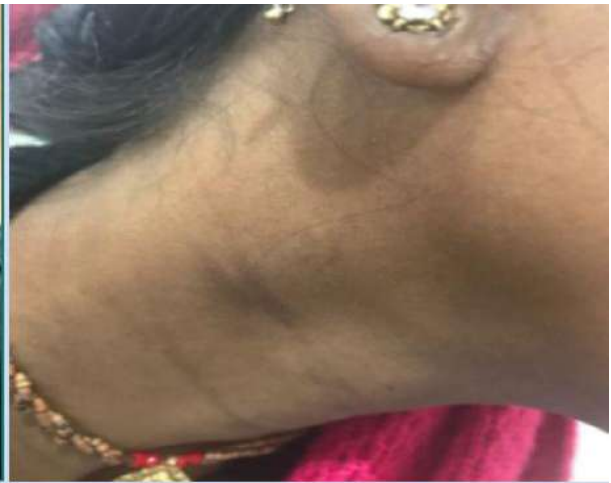This case offered a valuable insight into the power of homeopathy in managing conditions conventionally advised for surgery. Often, as practitioners, we hesitate to take up such cases assuming they are purely surgical, but this experience reaffirmed that with the right approach, even such cases can be managed gently and effectively through homeopathy. The patient, initially fearful of surgery and highly superstitious, responded positively to individualized treatment. The swelling reduced significantly, and surgery was completely

avoided. Beyond the physical healing, she experienced emotional transformation — becoming more confident and open to treatment. Once reluctant and hiding her neck with a dupatta due to embarrassment, she now carries herself with confidence and ease. This case is a living example of how homeopathy can reach where the surgeon's knife cannot, bringing not just cure, but a genuine smile on the patient's face.

The transformation



Sept 2021



Jan 2022

Acknowledgments

I take this opportunity to thank those who have helped and supported me personally and professionally during this case study

References

- [1] Bazemore AW, Smucker DR. Am Fam Physician. 2002;66(11):2103–2110.
- [2] Habermann TM, Steensma DP. Mayo Clin Proc. 2000;75(7):723–732.
- [3] Ferrer R. Am Fam Physician. 1998;58(6):1313–1320.
- [4] Gritzmann N. AJR Am J Roentgenol. 1985;144(4):907–913.