

---

Original Research Article

Volume 14 Issue 03

March 2025

---

## SUCCESSFUL MANAGEMENT OF SENILE ECZEMA: A CASE STUDY FROM DR. BATRA'S CLINIC

**Dr Smitha Naradas**

BHMS, Chief Homeopathic Consultant, Kukatpally Branch

Dr Batra's Positive Health Clinic Pvt. Ltd.

Email id: [smitan13@gmail.com](mailto:smitan13@gmail.com)

### Abstract

Senile eczema, a common dermatological condition in elderly individuals, presents as dry, papular eruptions with intense itching. This paper presents a 76-year-old male patient who visited DrBatra's, with a history of intense itching on his right knee significant dryness, redness, bleeding spots, with homeopathy within 15 days his lesions healed and no marks were left

### Keywords:

Dr Batra's, homeopathy, Senile eczema

### Introduction

Senile eczema, also known as asteatotic eczema or xerotic eczema, is a common skin condition affecting the elderly, characterized by dry, itchy, and inflamed skin. It occurs due to the skin's reduced ability to retain moisture as a result of aging, leading to impaired skin barrier function. The condition is exacerbated by environmental factors such as cold weather, frequent bathing, and the use of harsh soaps. Common symptoms include dryness, redness, itching, and the formation of papules or pustules. If left untreated, senile eczema can lead to complications like secondary infections, skin bleeding from scratching, and further

96

exacerbation of skin dryness, ultimately affecting the quality of life. Poor hygiene, chronic smoking, and excessive sugar intake may also contribute to the development and worsening of this condition.

### Case Profile

A 76-year-old male presented with dry, papular eruptions on his right knee for the past week, accompanied by intense itching. The patient reported excessive scratching, leading to bruised skin and minor bleeding, but no oozing. His medical history includes chronic smoking for 30 years, though he is non-diabetic and does not have hypertension. He works in agriculture and maintains poor hygiene, not using soap while bathing. He has not taken any medications, although his daughter-in-law applied Neosporin ointment and cleaned the affected area with Dettol. Additionally, the patient has a history of consuming excessive white sugar after meals and has experienced personal stress following the death of his wife six months ago, though they had been separated for the last 25 years. He has no known history of allergic asthma or rhinitis.

### Physical Generals

Diet	Non Vegetarian
Appetite	Normal
Desire	Sugar ++, Daily After Food Eats Only Sugar 2 Spoons
Aversion	Sour
Thermal Reaction	Hot Pt
Thirst	7-8 Glasses
Stools	Normal
Urine	Normal
Perspiration	Scanty
Sleep	Refreshing
Dreams	Nothing Specific

## Mental Generals –

The patient, a former farmer from Andhra Pradesh, has been inactive since leaving agriculture and currently resides with his second son. Married 50 years ago, he separated from his wife 25 years ago and maintained a relationship with another woman. He has two sons who live in Andhra Pradesh, while he stays with his second son's family. Known for his calm and composed nature, he rarely gets angry and is described by his daughter-in-law as highly sensitive but unhygienic. He is an adaptable person who never asks for anything and adjusts easily to situations. Despite his wife's passing six months ago, he does not exhibit signs of depression; instead, he appears content and happy, particularly enjoying time with his grandchildren. He spends most of his time watching television and does not engage in any work-related activities. Though he is supportive and helpful to his daughter-in-law, he remains largely inactive in daily life.

## Past History

NS

## Family History

N.S

## Case analysis

### Repertorial totality

Repertory used	Rubrics selected
<b>Kent Repertory</b>	<ul style="list-style-type: none"> <li>– Skin – Itching</li> <li>– Skin – blotches</li> <li>– Skin – crackling</li> <li>– Skin – fissures</li> <li>– Mind – ailment from – death of loved ones</li> <li>– Mind – ailment from - Emotionally suppressed from being</li> <li>– Generals - Smoking</li> </ul>

## Repertory screenshot

Remedies	ars.	staph.	lach.	op.	ph-ac.	acon.	ambr.	caust.	ign.	lyc.	nat-m.	rhust.	sulph.	vanil.	anthraci.	aur-m-n.	calc.	gels.	kal.
Serial Number	1	2	3	4	5	6	7	8	9	10	11	12	13	14	15	16	17	18	19
Symptoms Covered	2	2	2	2	2	2	2	2	2	2	2	2	2	2	2	2	2	2	2
Intensity	6	6	5	5	5	4	4	4	4	4	4	4	4	4	3	3	3	3	3
Result	2/6	2/6	2/5	2/5	2/5	2/4	2/4	2/4	2/4	2/4	2/4	2/4	2/4	2/4	2/3	2/3	2/3	2/3	2/3
Clipboard 4																			
SKIN - ITCHING	3	3	2	2	2	1	2	3	1	3	3	3	3	1	2	1	2	2	1
SKIN - BLOTCHES																			
SKIN - CRACKLING																			
SKIN - FISSURES																			
MIND - AILMENTS FROM - death of loved ones	3	3	3	3	3	3	2	1	3	1	1	1	1	3	1	2	1	1	2
MIND - AILMENTS FROM - emotionally suppressed; from being																			
GENERALS - SMOKING																			

## Selection of Remedy

**Constitutional:** Nat mur 200 – 1 dose – Itching & pricking sensation in skin

**Acute:** Rhus tox 6c daily

**Intercurrent:** Sulphur 30 given in 4<sup>th</sup> week

## Miasmatic approach

Symptoms	Psora	Sycosis	Syphilis	Tubercular
Skin – Itching	✓			
Skin – Blotches		✓		
Skin – Crackling			✓	
Skin – Fissures			✓	
Mind – Ailment from Death of Loved Ones			✓	✓
Mind – Ailment from Emotional Suppression		✓	✓	
Generals – Smoking (Miasmatic Approach)		✓	✓	✓

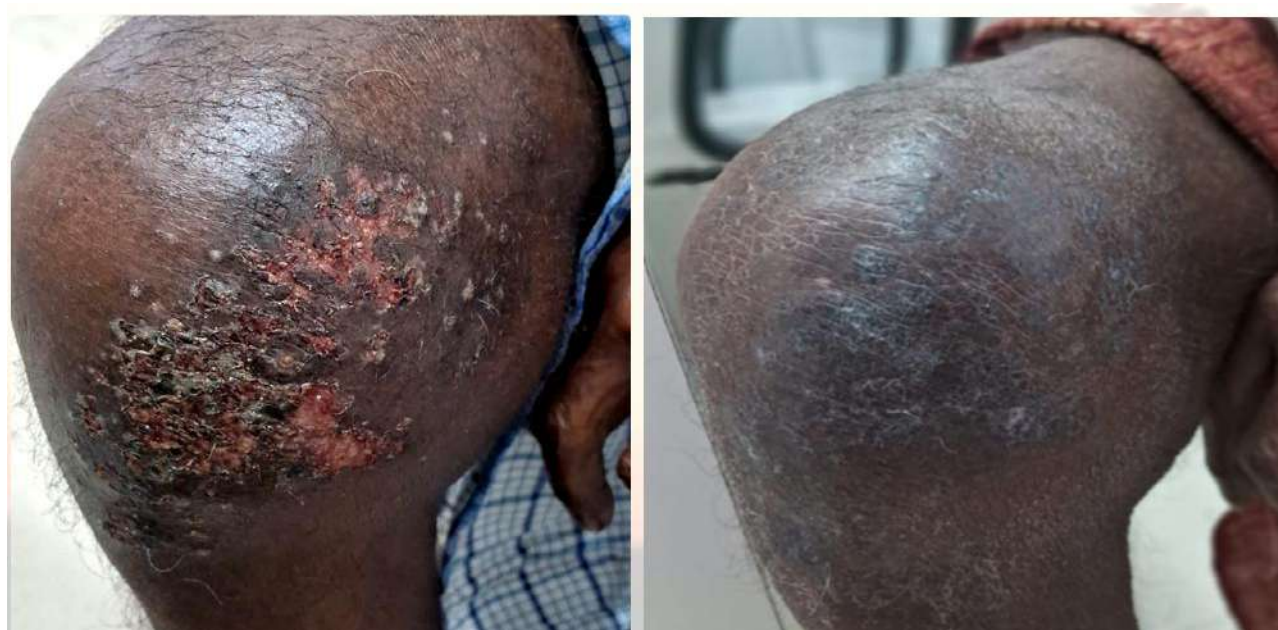## Results

<b>MONTHS</b>	<b>PROGRESS</b>	<b>PRESCRIPTION</b>
1 <sup>st</sup> month	Initial 15 days patient got totally alright, no skin complaints	Natrum mur 200 1 dose followed by Rhustox 6c

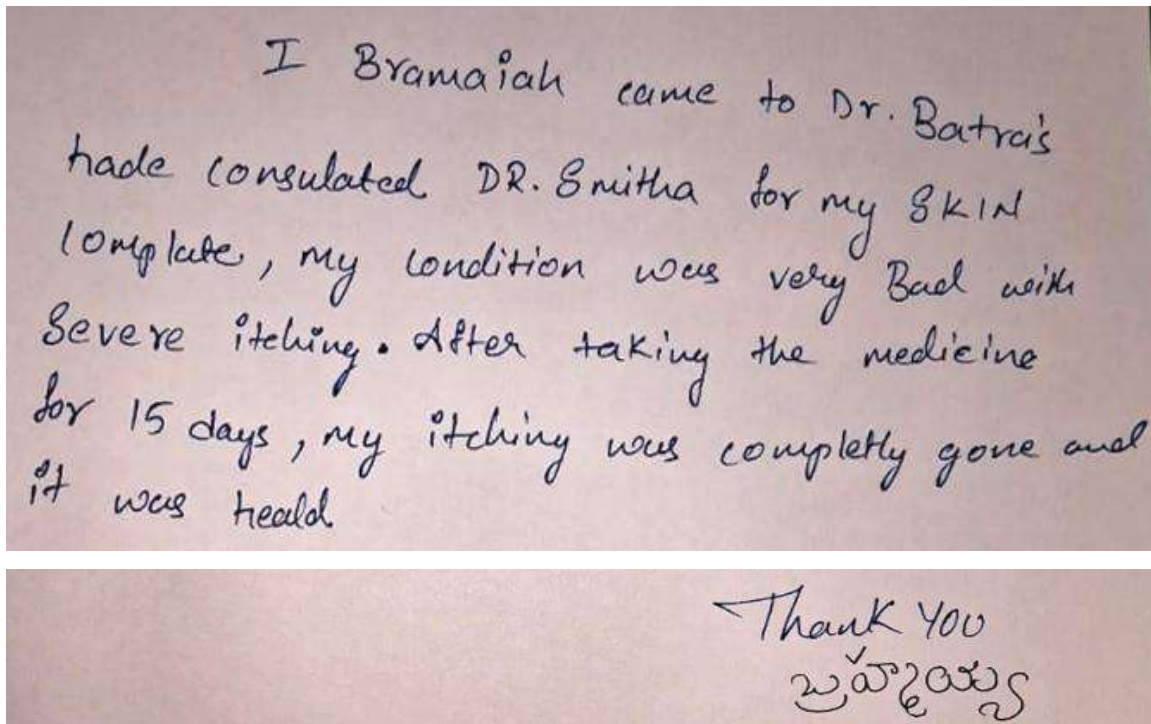
## Discussion & Conclusion

74-year-old suffering with dry, papular eruptions and intense itching on his right knee since a 30 years. He was a chronic smoker, and followed poor hygiene - including not using soap during bathing. He worked in agriculture and was exposed to environmental irritants daily, leading to bruised skin with bleeding spots. Despite initial treatment with allopathic creams and antiseptics, his condition showed no improvement. After homeopathy patient experienced significant relief, with itching subsiding, lesions healing completely, and no new eruptions forming. A holistic homeopathic approach focusing on miasmatic evaluation is crucial for effective treatment. Addressing the emotional and physical layers together can lead to deep-rooted healing and long-term relief.

## The transformation



## Testimonial



## Acknowledgments

I would like to express my gratitude to God, my peers for their unwavering support, and my mentors, Dr. Daniel and Dr. Smita Shinde, for their invaluable guidance.

## References

<https://doi.org/10.1186/s12974-021-02319-4>

<https://pmc.ncbi.nlm.nih.gov/articles/PMC7044141/>

<https://www.sciencedirect.com/science/article/pii/S2666328724000762>