

Original Research Article

Volume 13 Issue 11

November 2024

## SHOOKA DOSHA: FEATURE COMPARISON TO VARIOUS PENILE SKIN DISORDERS

**Dr Manish Sharma<sup>1</sup>, Dr Rajender Singh<sup>2</sup>, Dr Shikha<sup>3</sup>, Dr V.S Dahiya<sup>4</sup>**

<sup>1</sup>Ph. D Scholar, Department of Shalya Tantra, SKAU Kurukshetra

<sup>2</sup>Associate Prof, M.D. (Shalya), Ph.D. (Ayu), Department of Shalya Tantra, SKAU Kurukshetra

<sup>3</sup>Assistant Professor, M.D Swasthavritta, Department of Swasthavritta and Yoga, BMU, Asthal Bohar, Rohtak

<sup>4</sup>Dermatologist, MBBS, M.D, Department of Dermatology.

**Corresponding Author** - Dr Manish Sharma, Ph. D Scholar, Department of Shalya Tantra, SKAU Kurukshetra.

### Abstract

It has been seen in ayurveda text deliberately by name of shook doasha alongside their administration these gathering of sickness are existing in various structure and that is only the tip of iceberg or lesser closer to the current issue of penile disease. shook doasha is created by in any individual who attempts to build the size of penis with ill-advised technique which prompts 18 sorts of shook janya disease. All sign and symptom told by Acharyas in different text can also be related with modern penile skin disorder.

**Keywords:** Sushruta samhita , Shook dosha, Penile disorder, skin disorder, micropenis.

### Introduction

The skin of the penis is loose and stretchy. The stretchy skin allows for changes in penis size during erection. For penile enlargement people use different kind of medicine and procedure which are not mentioned in ayurvedic texts leads to Shooka dosha as mentioned by Acharaya sushruta . Any of the eighteen different types of Śukadosha the disease may affect the genital (penis) of a man who foolishly resorts to the practice of getting it abnormally elongated and swollen by plastering it with Śhooka and not in the usual official way.

The penis is one of the outer part of the urinary framework and regenerative framework. The penis has three sections.

- Root : It exists between a stringy layer in your perineum (the space among rear-end and privates) and connective tissue (shallow perineal pocket) in pelvic floor. The root contains tissues that assist with getting an erection, which considers infiltration during sex, and muscles that assist with eliminating pee and semen (discharge) from urethra.
- Body (shaft). The shaft of the penis seems to be a cylinder. It swings from a joint between the left and right hip bones. It contains erectile tissues: two cylinder like loads that run the length of the highest point of the penis (corpora cavernosa) and one cylinder like chamber that runs along the lower part of penis (corpus spongiosum), which additionally encompasses the urethra. These chambers contain great many spaces that load up with blood during erection.
- Glans penis (head). The glans is the tip of the penis. It contains the finish of the urethra (urethral meatus), which is where pee and semen exit the body. The prepuce is an external layer of skin that covers the glans.

*अकर्मत् शेफसो वृद्धि यो अभिवान्छति मूढधीः / व्याधयः तस्य जायन्ते दश च अष्टौ च शूकजाः //*

*(m.a n.i 47/1)*

Shook dosha is made up of two words “shook” means treatment and “Dosha” means disease produced so shook dosha is the disease produced due to remedy applied<sup>1</sup>.

Diseases, which result from such malpractices, are known as,—

1. Sarshapikā,
2. Ashthilikā,
3. Grathitam,
4. Kumbhikā,
5. Alaji,
6. Mriditam,
7. Sammudha-pidakā,
8. Avamantha,
9. Pushkarikā,
10. Sparśahāni,

11. Uttamā,
12. Śatoponaka,
13. Tvakapāka,
14. Śonitārvudam,
15. Mānsārvudam,
16. Mānsapāka,
17. Vidradhi
18. Tilakālak.

Detailed description of shook dosha are mentioned in sushruta Samhita , ashtang sangraha and madhav nidana. The shook doshas are 18 in number among them 4 are incurable.

Micropenis is an abnormally little penis that is found in outset or youth. It's normally the consequence of a lack of fetal testosterone. Individuals with micropenis are as yet ready to pee (pee) and have erections. Micropenis is extremely intriguing, influencing around 0.6% of individuals around the world.

Size : Decide micropenis size by the extended penile length (SPL). The legitimate method for laying out the SPL is to tenderly stretch the penis, hold it near the body and measure it from tip to base of the penis. Analyze micropenis assuming the length is under 2.5 standard deviations beneath the normal. 4

- The typical extended penile length (SPL) for grown-up guys is 5.25 inches. A SPL of 3.67 inches or less shows a grown-up micropenis.
- The typical SPL for an infant is 1.4 inches. A SPL of 0.75 inches or less demonstrates a baby micropenis.

A great many people with a micropenis capability typically with regards to sex. A micropenis doesn't influence capacity to pee, stroke off or arrive at climax. Micropenis doesn't need to be an obstruction to intimacy.5




In the public arena, penis size is frequently erroneously likened with manliness. Thus, those with micropenis could feel humiliated or reluctant. Yet, it's essential to comprehend that penis size doesn't have anything to do with manliness. Individuals with more modest than-normal penises actually lead sound, physically dynamic lives.6



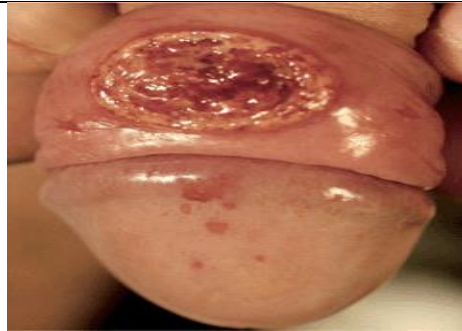
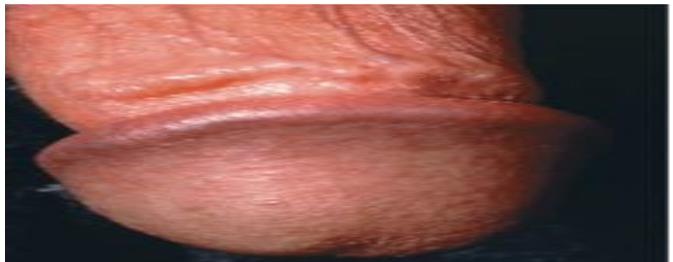
**Shook doshas as explained in ayurveda Samhita corelated with modern penile skin disorder (Table1)**

Sr no.	Name of shook dosha	Cause /Dosh a involv ed	Symptom/ features	Modern disease
1	Saraspika	Doosh it yoni / Kapha rakta dosha	पिडका कफरक्ताभ्यां ज्ञेया सर्षपिका बुधैः   4   White mustard-like size & shape boil	Lichen nitidus
2	Asthilika	Poiso nous bhalla tak \ Vayu dosha	शूकैस्तु विषसम्भुगैः Bhallatak (Semecarpus anacardium) use of poisonous plant. Hard Pidika size and shape of (Lohkarasya bhaandee= Iron pan )	Molluscum contagiasu m
3	Grathita	kapha dosha	शूकैर्यत् पूरितं शश्वद्रथितं तत् कफोत्थितम्  6  Pidika resembling cyst. Penis continuously discharge til (Sesamum indicum) like paste	Gonorrhoea
4	Kumbhika	Rakta pitta	कुम्भीका रक्तपित्तोत्था जाम्बवास्थिनिभाऽशुभा  6  Seed of Jamun (Syzygium cumini) like colour and shape boil	Syphilis
5	Alaji	Rakta pitta	A dreadful abscess which is of a red and white colour studded over with blisters or exuding vesicles	Migratory neurolytic erythema
6	Mridita	vata	मृदितं पीडितं यत्तु संरब्धं वायुकोपतः  7  Swelling of penis after rubbing of penis	Chancroid
7	Sammudha pidika	Vata rakta	पाणिभ्यां भृशसम्मूढे सम्मूढपिडका भवेत्  8  Swelling of penis after rubbing forming ulcers.	Sclerosing Lymphangit is of Penis
8	Avamanth	Kapha rakta	दीर्घा बह्व्यश्च पिडका दीर्यन्ते मध्यतस्तु याः   सोऽवमन्थः कफासृग्भ्यां वेदनारोमहर्षकृत्  9  Multiple elongated pidika break open centrally with pain	scabies


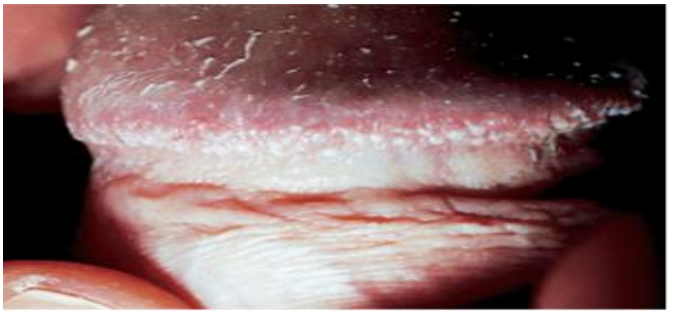
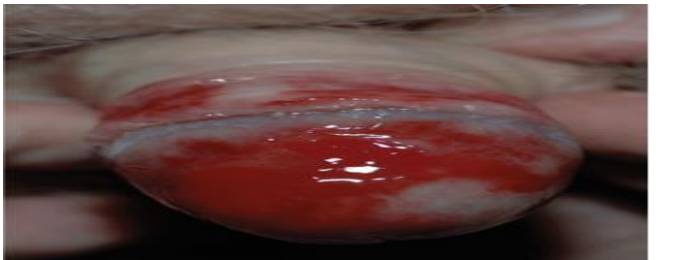
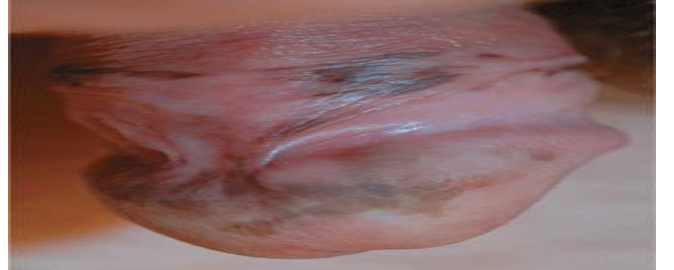

9	Pushkarika	Pitta rakta	पित्तशोणितसम्भूता पिडका पिडकाचिता । पद्मपुष्करसंस्थाना ज्ञेया पुष्करिकेति सा ।10] Big rash resembling lotus flower with many pidika	Pearly penile papules
10	Sparshhani	Rakta	जनयेत् स्पर्शहानिं तु शोणितं शूकदूषितम् ।11] Loss of sensation in penis.	Plasma cell balanitis (Zoon's)
11	Uttama	Rakta pitta	मुद्गमाषोपमा रक्ता पिडका रक्तपित्तजा । उत्तमैषा तु विज्ञेया शूकाजीर्णनिमित्तजा ।12] Red coloured papules resembling shape and size of green gram\ black gram .	Lentiginos es
12	Shatpaunaka	Vata rakta	छिद्रैरणुमुखैर्वस्तु चितं यस्य समन्ततः । वातशोणितजो व्याधिर्विज्ञेयः शतपोनकः ।13] Multiple opening with discharge.	Genital Herpes
13	Twakpakka	Pitta rakta	पित्तरक्तकृतो ज्ञेयस्त्वक्पाको ज्वरदाहवान् ।14] Inflammation with fever and burning sensation.	Lichen Sclerosus
14	Shonitarbuda	Vata rakta	कृष्णौः स्फोटैः सरक्तैश्च पिडकाभिश्च पीडितम् । यस्य वस्तु रुजश्चोग्रा ज्ञेयं तच्छोणितार्बुदम् ।15] Blackish red colour eruption with pain .	Penial intra epithelial neoplasia
15	Masaarbuda		मांसदोषेण जानीयादर्बुदं मांससम्भवम् ।16] Mamsa (penis tissue) swelling and involvement	Ca penis SCC
16	Manasapaka	Trido sha	शीर्यन्ते यस्य मांसानि यत्र सर्वाश्च वेदनाः विद्यात्तं मांसपाकं तु सर्वदोषकृतं भिषक् ।16] Mamsa ( Penis tissue) inflammation and ulcer formation with slough	Balanitis
17	Vidhradhi	Trido sha	विद्रधिं सन्निपातेन यथोक्तमभिनिर्दिशेत् ।17] Abscess on penis with pain and discharge.	Penile Abscess
18	Tilkalka	Trido sha	कृष्णानि चित्राण्यथवा शूकानि सविषाणि च । पातितानि पचन्त्याशु मेढ्रं निरवशेषतः । कालानि भूत्वा मांसानि शीर्यन्ते यस्य देहिनः । सन्निपातसमुत्थानं तं विद्यात्तिलकालकम् ।18] The tissue of penis gets blackened and started falling off with suppuration	Fournier Gangrene

**Modern penile skin disorder with their symptoms and Pictures (Table2)**




Sr no .	Disease	Symptom	Picture
1	Lichen Nitidus	Violaceous flat-topped papules, discrete or confluent. Lacy white surface pattern most commonly on glans. Older lesions may have grayish hue with melanin incontinence. Annular lesions occur on glans and shaft	
2	Molluscum contagiosum	Molluscum contagiosum is a viral skin infection that causes one or many raised, pearl-like bumps (papules) on skin	
3	Gonorrhoea	Urethral discharge ranging from scanty and clear to purulent and copious	




4	Syphilis	A painless ulcer or chancre on the mucocutaneous site of inoculation. Associated with regional lymphadenopathy	
5	Migratory Necrotic erythema	Manifestation of glucagonoma syndrome.  Painful erythematous plaques, glistening surface, serpiginous border surrounded by scaling.	
6	<b>Chancroid</b>	Tender papule with erythematous halo that evolves to pustule, erosion, and ulcer. <i>Ulcer is usually quite tender or painful.</i>	
7	Sclerosing Lymphangitis of Penis	Clinical findings: Painless, firm, at times nodular, translucent serpiginous cord appears suddenly,	



8	Penile scabies	Scabies on the penis can cause intense itchiness in genital area along with tiny, raised pimple-like bumps on and around penis	
9	Pearly penile papules	Skin-colored 1- to 2-mm, discrete, domed papules evenly distributed circumferentially around the corona, giving a cobblestone pattern.	
10	Plasma cell balanitis (Zoon)	Asymptomatic red glistening plaque(s) on glans penis	
11	Lentiginoses	Tan, brown, intense blue-black; usually variegated, 5- to 15-mm macules.	
12	Genital Herpes	fever, headache, malaise, myalgia, peaking within the first 3-4 days after onset of lesions, resolving during the subsequent 3-4 days. <i>Erythematous papules</i> initially evolve to <i>vesicles</i> or <i>pustules</i> , which	



		become <i>eroded</i> as the overlying epidermis sloughs	
13	Lichen Sclerosus	Pruritus, burning; pain with ulceration. <i>Clinical findings:</i> Early: erythema ± hypopigmentation	
14	Penial intra epithelial neoplasia	Erythematous patches and papules (pigmented papules). <i>Arrangement:</i> Solitary, clustering, confluence, plaque(s) formation. <i>Distribution:</i> Mucosa and anogenital and inguinocrural skin.	
15	Ca penis SCC	Solitary, well-defined, irregularly bordered, red patch with a glazed-to-velvety surface hyperkeratosis on the penis	

16	Balanitis	Inflammation of the head of the penis, which can cause pain, swelling, itching, rash, and discharge. It's often caused by poor hygiene.	
17	Penile Abscess	present with a localized penile swelling and painful erections	
18	Fournier's Gangrene	Fournier's gangrene is a rare, fulminant, but usually a localized disease of the scrotum and penis. fever and pain with brownish-black discolouration of the penis,	

### Aims and objectives

Aimed to review the features of Shook Dosha in Ayurveda and compare these features with modern penile skin disease .

### Materials and Methods

The search of *Ayurveda* literature regarding shook dosha and modern literature regarding Penile disease , and journals were done. Then, the collected matters were reviewed and analyzed and disease were compared to modern penile skin disease for further classification according to symptom presentation.

### SADHYATA-ASADHYATA (PROGNOSIS) as per Ayurvedic literature

*तत्र मांसार्बुदं यच्च मांसपाकश्च यः स्मृतः । विद्रधिश्च न सिध्यन्ति ये च स्युस्तिलकालकाः ॥१८॥*

Among 18 types of *shook dosha* मांसारुद (Ca penis), मांसपाक (cellulitis), विद्रधि (Abscess) तिलकालक (Gangrene) are considered incurable.

## Discussion

Ayurvedic literature has mentioned shook doshas as complication of ill-defined treatment used for penile enlargement but the no. of disease mentioned are not only covers these complications but other diseases also from STD (Sexually tr

ansmitted disease) to Fournier's gangrene up to carcinoma penis. So, it is injudicious to limit this disease just under shook doshas. Shook doshas are concise form of disorders in ayurvedic texts but penile skin disorders are more elaborative. Now time has come that, this topic should be consider for further research. So that, ayurvedic treatment defined for these disorders can be proved scientifically and used in conjugation with dermatological perspectives.

## Conclusion

It is a sincere effort to review *shook dosha* mentioned in ayurvedic classical text and correlate its features to various skin penile disease in modern science. The disease mentioned in ayurvedic classics have comparable clinical features as disease observed in modern dermatology practice.

**Financial support and sponsorship** -Nil.

**Conflicts of interest** -Nil.

## References

1. Acharya YT, Acharya RM, Nidana sthana . Sushruta Samhita of Sushruta Nibandha Samgraha Commentary. 20058th ed. Varanasi Chaukhambha Orientale:375 Ch. 14., Ver. 3
2. Sushruta, Sushrutha samhita, Nibandasangraha commentary of sri Dalhanacharya edited by Acharya Yadavji Trikamji, Choukhamba surabharati prakashan, Varanasi, reprint on 2017, Nidana sthana, 6 th chapter, 15th shloka.
3. Shashtri S, Upadhyaya YN, editors. Madhava Nidana, Sanskrit Commentary by Sri Vijayarakshita and Sri Kanthadatta, Shukadosh Nidana. Ch. 48. Varanasi: Chaukhambha Prakashana; 2016. p. 175

4. Rai RK Bangsen Samhita (Chikitsa Saar Samgraha); Shookdosha Rogadhikar. Ch. 56., Ver. 1-35. 2010 Varanasi Pracchya Prakashan:489–92.
5. Custer J, Rau R. The Harriet Lane Handbook, 18th ed. In: S Ballel, P McIntosh, eds. Endocrinology . 269-300. Philadelphia: Elsevier Mosby.
6. Hatipoğlu N, Kurtoğlu S. Micropenis: Etiology, Diagnosis and Treatment Approaches (<https://www.ncbi.nlm.nih.gov/pmc/articles/PMC3890219/>). *J Clin Res Pediatr Endocrinol*. 2013 Dec; 5(4): 217–223.
7. Tsang, S. When Size Matters: A Clinical Review of Pathological Micropenis ([https://www.jpeds.org/article/S0891-5245\(09%2900140-0/pdf\)](https://www.jpeds.org/article/S0891-5245(09%2900140-0/pdf))). *J Pediatr Health Care* . 2010; 24, 231-240.
8. “Shook Dosha (Complication of Recipes use for Penile Enlargement) in Ayurveda A Critical Review” Varsakiya, Jitendra Nathabhai; Kumar, Mahesh1, *AYUHOME* 7(2):p 55-61, Jul–Dec 2020. | DOI: 10.4103/AYUHOME.AYUHOME\_6\_21
9. “Shook dosha : Diseases due to Artificial sexual stimulants, size enhancers “ article by Dr Raghuram Y.S MD & Dr Manasa.
10. DR.KANJIV LOCHAN & BRAHMANAND TRIPATHI Madhava nidana (AN ANCIENT TEXT ON AYURVEDIC DIAGNOSTICS) 2014 edition Chaukhambha surbharati parkashan.
11. Srikanta MK Ashtang Hridaya of Vagbhata, Sutra Sthana.. 2009 1st ed. Varanasi Chaukhambha Krishnadas Academy:121 Ch. 16., Ver. 5.
12. Shashtri S, Upadhyaya YN, editors. Madhava Nidana, Sanskrit Commentary by Sri Vijayarakshita and Sri Kanthadatta, Shukadosh Nidana. Ch. 48. Varanasi: Chaukhambha Prakashana; 2016. p. 175
13. Fitzpatrick’s colour atlas and synopsis of clinical dermatology klauswolf, Richard johnson , Arturo P. Saavedra .Section 34 disorder of genitalia, perineum and anus p. 2260-2304.
14. Illustrated synopsis of Dermatology and Sexually Transmitted Disease, Neena Khanna, Prof. Department of Dermatology and Venereology AIIMS, New Delhi, P. 230- 249.
15. Essential in Dermatology, venereology & leprology, Ramesh Bansal, MBBS, MD ( skin, VD and leprosy) P. 397-404