

Original Research Article

Volume 14 Issue 03

March 2025

HOMEOPATHIC MANAGEMENT OF BRONCHITIS

Dr Prakriti Jain

B.H.M.S, Chief Homeopathic Consultant, Bhopal Branch

Dr Batra's Positive Health Clinic Pvt. Ltd.

Email id – drprakriti13297@gmail.com

Abstract

Inflammation of the bronchial tubes is termed as bronchitis, often caused by viral infections, smoking, or environmental triggers, leading to persistent coughing, chest discomfort, and breathlessness. This paper focuses on 38 years old chronic smoker with history bronchitis came to Dr Batra's for homeopathic treatment, after which the patient experienced significant improvement, becoming symptom-free and regaining his health and confidence.

Keywords:

Bronchitis, homeopathy, Dr Batra's

Introduction-

Bronchitis is an inflammation of the bronchial tubes, which carry air to and from the lungs. It is commonly caused by viral infections, bacterial infections, or exposure to irritants like smoke, dust, and pollutants. Long-term inflammation, leading to persistent cough, shortness of breath, and frequent respiratory infections. If left untreated, bronchitis can lead to complications such as pneumonia, worsening of respiratory symptoms, or the development of chronic lung conditions.

Case Profile-

The patient complains of a persistent dry cough occurring in short intervals but lasting for a long duration, especially in the evening or when transitioning from air-conditioned to

warmer areas. He also experiences chest heaviness and a burning sensation in the mid-sternum, along with continuous coughing that is followed by pain in the neck and throat. The symptoms first appeared in 2009, with intermittent episodes of cough and cold that have continued to occur over the years. Despite using allopathic medicine since 2009, the patient found no relief, and the condition has progressively worsened. Initially, the symptoms began in Goa and became more severe after moving to Bhopal. The patient's condition is aggravated by changes in weather, atmosphere, food, and the transition from air-conditioned environments to hot, humid weather.

Physical Generals

Diet	Mixed
Appetite	Good
Desire	Salty & sweet
Aversion	N.S
Thermal Reaction	Chilly
Thirst	3 lit per day
Stools	Occ. Constipated
Urine	Normal
Perspiration	Only on exertion
Sleep	Sound
Dreams	Does not remember

Mental Generals-

The patient is introverted by nature, often feeling anxious and prone to anger. He has a fear of his health and tends to be impulsive and fastidious in his habits. Raised in a long-distance family setting, he maintains good relationships with friends and is able to mingle easily in social situations. However, he tends to overthink, which can exacerbate his anxiety and anger. Despite these traits, he finds comfort in watching sunsets, which helps him relax and reflect.

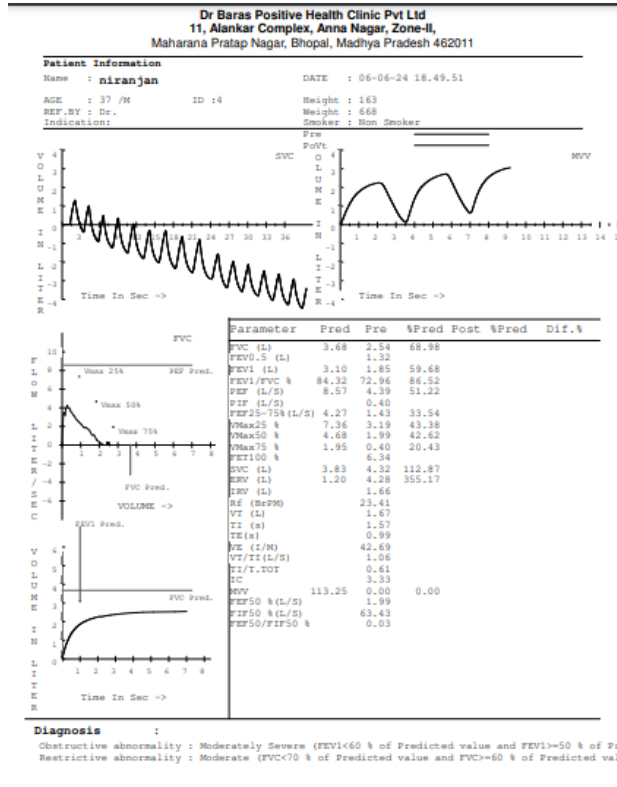
Past History

N.S.

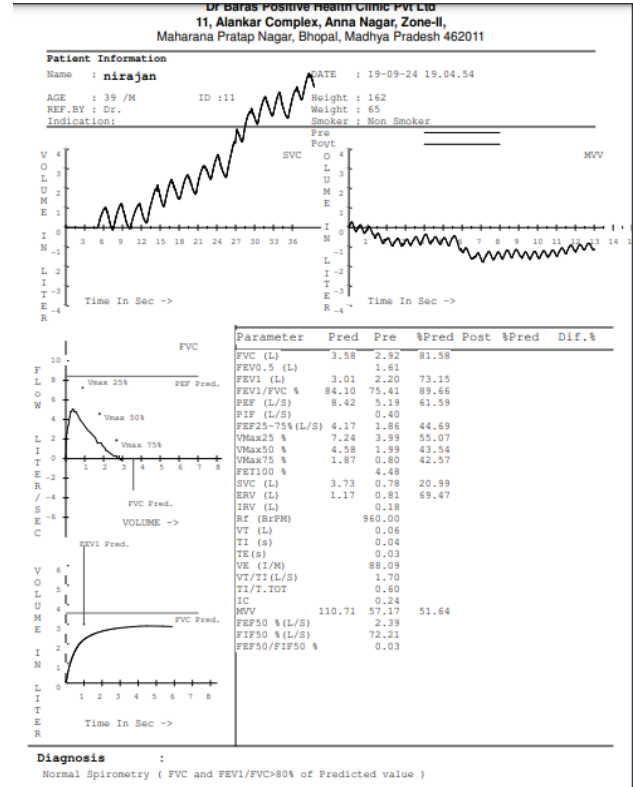
Family History

Father-HTN

Examination



06.06.2024
Obstructive/Restrictive abnormality
Moderately severe FEV1>50%



19.09.2024
Normal spirometry FEV1 >80%

Case analysis

Mind, anger, ailments after anger, with anxiety

Mind, anxiety, chill, during

Mind, fastidious

Mind, impulsive

Reportorial Chart

Remedies	ars.	calc.	lyc.	phos.	rhus-t.	puls.	kali-c.	spong.	sulph.	nux-v.	ip.	lach.	ant-t.	caps.	ferr.	nat-m.	bry.
Serial Number	1	2	3	4	5	6	7	8	9	10	11	12	13	14	15	16	17
Symptoms Covered	6	5	5	5	5	4	4	4	4	4	4	4	4	4	4	4	4
Intensity	13	9	8	8	7	11	10	9	9	8	7	7	6	6	6	6	5
Result	6/13	5/9	5/8	5/8	5/7	4/11	4/10	4/9	4/9	4/8	4/7	4/7	4/6	4/6	4/6	4/6	4/5
Clipboard 3																	
RESPIRATION - ASTHMATIC	3	2	2	2	1	3	3	3	3	2	3	2	2	2	2	2	2
RESPIRATION - BREATHLESS																	
RESPIRATION - CHILL; during	3		1	1	2	3	3		1	2	2	1		1	2	1	1
RESPIRATION - CHRONIC OBSTRUCTIVE PULMONARY DISORDER	1	1	1	1				1					1				1
RESPIRATION - COMPLAINTS of respiration	3	3	2	3	2	3	2	3	3	3	1	3	2	1	1	2	1
RESPIRATION -																	

Selection of Remedy

Remedy	Reasons
Constitutional Arsenic album 200 – 1 dose weekly	Suitable to patient ,fastidiousness &fear of diseases
Acute Kali carb-30	Difficult respiration Shortness of breath in morning. Respiration impeded on walking quickly, or in morning Stitches in sternum and r. side of chest through to back, when taking inspiration. Tearing in sides of chest Spasmodic asthma (in the morning); > by sitting up and bending forward, resting head on knees). Anxious oppression at chest Obstructed respiration awakes him at night Wheezing in chest
Intercurrent Natrum sulp 6x	Damp houses, basements, worse in rainy weather, any change from dry to wet

Miasmatic approach

Symptoms	Psora	Sycosis	Syphilis	Tubercular
Mind, anger, ailments after anger, with anxiety	yes	yes	yes	yes
Mind, anxiety, chill, during	yes	yes	yes	yes
Mind, fastidious				yes
Mind, impulsive	yes	yes	yes	yes
Miasmatic predominance	<u>ys</u>	<u>yes</u>	<u>yes</u>	<u>yes</u>

Results

Month	Progress	Prescription Given
1st month	No significant improvement initially; coughing every alternate evening; stopped smoking, mild throat itching and dryness in the mouth.	Ars alb 1, Kali Carb 30 bd, Nat Sulp 6x
2nd month	Coughing improved, skin on legs better; no breathing issues; mild coughing 1-2 times.	Ars alb 1, Sac Lac, Nat Sulp 6x
3rd month	Respiratory issues significantly improved, no dependence on allopathic medicine; mild coughing and throat itching.	Sac Lac, Nat Sulp 6x
4th month	Mild coughing persisted, no major throat pain; skin improving, overall better health.	Sac Lac, Nat Sulp 6x
5th month	Continued improvement in health, coughing reduced further; stable skin condition, no chest pain or expectoration.	Sac Lac, Nat Sulp 6x
6th month	Respiratory symptoms nearly resolved; coughing rare and mild; feeling more energetic.	Sac Lac, Nat Sulp 6x
7th month	Significant improvement; minimal throat issues and coughing.	Sac Lac, Nat Sulp 6x
8th month	Very few coughing episodes; overall health remained stable.	Ars alb 1, Sac Lac, Nat Sulp 6x
9th month	Almost fully recovered, no major symptoms; mild coughing occasionally.	Sac Lac, Nat Sulp 6x
10th month	Stable health, mild coughing; no significant issues.	Sac Lac, Nat Sulp 6x
11th month	Nearly fully recovered; no respiratory issues, skin improved.	Sac Lac, Nat Sulp 6x
12th month	Full recovery; no symptoms of coughing or respiratory problems; overall health stable.	Sac Lac, Nat Sulp 6x

Discussion& Conclusion

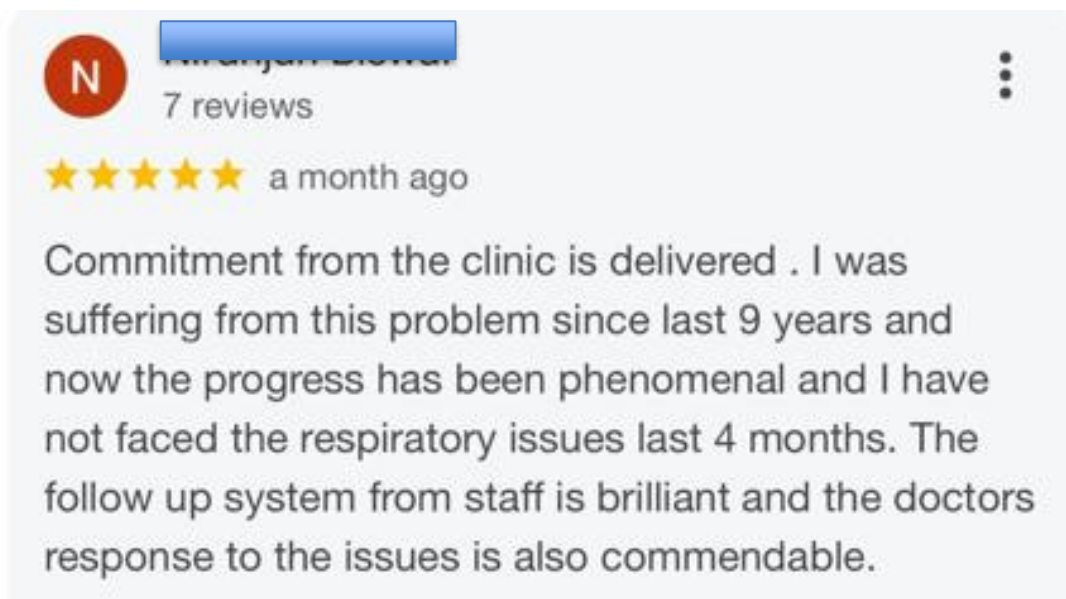
Discussion

This case involves a 32-year-old male with a long-standing history of dry cough, the severity of the condition increased as he moved from Goa to Bhopal, suggesting that the change in atmospheric conditions contributed to the exacerbation. Homeopathic remedies focused on treating the underlying causes, such as stress, environmental changes, and respiratory discomfort.

Conclusion:

This case highlights the effectiveness of homeopathy in managing chronic respiratory issues like bronchitis, especially when conventional treatments fail to provide relief. The patient's condition gradually improved over several months, with reduced coughing, alleviated chest pain, and enhanced overall health. Homeopathy, with its personalized approach, provided long-term relief and stability in respiratory health.

Patient testimonial



Acknowledgments

I take this opportunity to thank those who have helped and supported me personally and professionally during this case study.

References

1. Hahnemann S. Organon of medicine. B. Jain publishers; 2005.

2. Boericke W. Pocket manual of homoeopathic Materia Medica & Repertory: comprising of the characteristic and guiding symptoms of all remedies (clinical and pathogenetic) including Indian Drugs New Delhi, India: B Jain publishers; 2002.
3. Clarke JH. A dictionary of practical materia medica. 2 vols.[in 3]. 1900.
4. Kent JT. Lectures on homoeopathic materia medica. New Delhi, India: B Jain Publishing Company; 1980.
5. Lilienthal S. Homoeopathic therapeutics. B. Jain Publishers; 1998.
6. Kent JT. Lectures on Homeopathic Philosophy. Sittingbourne, Homeopathic Book Service. 1990.
7. Clarke JH. The Prescriber: A dictionary of the new therapeutics. Homeopathic Publishing Company; 1900.