

Original Research Article

Volume 14 Issue 01

January 2025

ALOPECIA AREATA TREATED WITH INDIVIDUALIZED HOMOEOPATHIC MEDICINE: AN EVIDENCE BASED CASE REPORT

***Dr Dariker Bateilin Kharmujai¹, Dr Vandana Mishra²**

¹Lecturer, Department of Homoeopathic Materia Medica, North Eastern Institute of Ayurveda and Homoeopathy, Mawdiangdiang, Shillong, Meghalaya, India

²PG Scholar, Department of Homoeopathic Materia Medica, North Eastern Institute of Ayurveda and Homoeopathy, Mawdiangdiang, Shillong, Meghalaya, India

*Corresponding Author's Email ID: datheikhar@gmail.com

ABSTRACT - Introduction -Alopecia Areata is a form of alopecia that affects hair follicles. It is an auto-immune disease and can be found in any age or sex. **Case summary** : A 50 year old female patient who had several bald patches on her scalp and was not getting any changes with conventional treatment. The patient has been diagnosed with Alopecia Areata and wanted to take homoeopathic treatment . Thuja was prescribed based on totality of symptoms, repertorial analysis and homoeopathic individualized medicine. After Homoeopathic treatment there was significant improvement seen with complete disappearance of bald patches without recurrence.

Keywords: Alopecia Areata, Autoimmune , Homoeopathy, Thuja

INTRODUCTION – Alopecia Areata has an autoimmune basis and there is a strong genetic component, with family history in approximately 20% of cases. This usually presents with well-defined, localized , non-scarring patches of alopecia, usually on the scalp. A diffuse pattern can

uncommonly occur on the scalp.^[1] The disease may be limited to one or more discrete, well-circumscribed, round, or oval patches of hair loss on the scalp or body. But in some cases, it may affect the entire scalp is known as alopecia totalis or the entire body is known as alopecia universalis.^[2] In diffuse alopecia areata cases prognosis may be bad.^[3] In most patients the onset is within the first 3 decades of life, although alopecia areata can start any age. The sex incidence is probably equal. ^[4] Psychosocial stress being one which has been reported to play a role in the onset and/or exacerbation of alopecia areata.^[5] AA is also associated with psychiatric and medical comorbidities including depression, anxiety, and several autoimmune disorders. Diagnosis is made by Clinical history, the pattern of alopecia, clinical examination, in diffuse cases, trichogram and biopsy are advised. ^[6]

There is no particular treatment for Alopecia Areata however topical immunotherapy, intralesional and topical or systemic corticosteroids are used in such patients in allopathic medicine of science. Homoeopathic treatments can offer gentle and safe treatment for patients suffering from Alopecia Areata . Homoeopathy treats the person individually as a whole. This includes a detailed medical history of the patient, family and causative factors. Any underlying predisposition factor and susceptibility is also considered. There are many Homoeopathic medicines for Alopecia , naming few of the remedies like Alumina, Arsenicum album, Floricum acidum, Graphites, Natrum muraticum, Nitricum acidum, Phosphoricum acidum, Phosphorus, Pix liquida, Selenium, Sepia, Syphilinum, Thallium, Vinca minor etc. ^[8]

CASE REPORT

HISTORY- A female patient of 50 year old came to the OPD and presented with multiple bald patches of hair loss which troubled her over a year. She was concerned about her condition as she did tried conventional treatments for the same complaint but could not get much benefit. On examination there were localized hair loss with two bald patches on the vertex region, shedding of hair in circumscribed manner with irregular margins, frontal hair line were intact , no recession/ visible damage of hair seen , volume of hair is very thin and the texture of hair is very dry, brittle and lusterless with split ends. There were more than 5 to 6 easily extractable hairs indicating a positive pull test and active hair loss. The patient came to the OPD as she had no hope in regards the alopecia especially at such age of her life. She is a working woman who

suffers from lifestyle problems gastric troubles mostly doesn't like company, dislike fatty oily food & has profuse perspiration. She didn't have any significant medical history or any family or genetic history.

The following characteristic symptoms were considered for the repertorization.

1. Absent-minded
2. Company aversion to
3. Fear - approaching him-of others
4. Indolence-Aversion to work
5. Perspiration profuse-night
6. Aversion to fatty food
7. Hair falling
8. Hair dryness
9. Hair lusterless

Repertorisation was done using Hompath8 Software (complete repertory). (7)

Table 1: Repertorization as obtained by using HOMPETH software

Remedy Name	Thuja	Sulph	Nat-m	Phos	Kali-c	Lyc	Sep	Chin	Graph
Totality	19	17	17	16	15	14	14	13	12
Symptom Covered	8	7	6	8	8	7	6	7	7
[C] [Mind]Absent-mindedness:	1	2	3	2	2	2	3	1	2
[C] [Mind]Company.Aversion to, agg.:	2	2	4	1	1	2	2	2	1
[C] [Mind]Fear.Approaching.Others, of:	2			1	1	2	1	1	1
[C] [Mind]Indolence.Aversion to work:	2	3	3	3	2	2	3	3	3
[C] [Perspiration]Profuse.Night:	3	3	2	3	3	2		2	1
[C] [Head]Hair.Affections of.Falling out, alopecia:	3	3	3	3	3	3	3	1	3
[C] [Head]Hair.Affections of.Dryness:	4	2		2	2				1
[C] [Head]Hair.Affections of.Lusterless:	2								
[C] [Generalities]Food and drinks.Fats and rich food.Aversion:		2	2	1	1	1	2	3	

INTERVENTION

First prescription: On 25 November 2023, Thuja 200C, 1 dose.

Basis of prescription: Medicine selected on the basis of individualisation, symptom totality and in consultation with Materia Medica was Thuja. Thuja was chosen as it covers the totality of symptoms. Thuja 200C, once for 2 weeks was prescribed.

On subsequent follow-ups, for next 2 months potency was same based on the assessment of improvement in bald patches & later following month the potency was increased seeing the improvements.

FOLLOW UPS AND OUTCOMES

The follow ups was done monthly with proper evaluation & was prescribed accordingly. The elaborate case follow ups are explained in a summarized way in Table no 2.

TABLE NO. 2

DATE	SYMPTOMS	PRESCRIPTION	REMARKS
25/11/2023	Hairfall in multiple patches.	Thuja 200/ 1dose(5 pills), PL/ OD for 2 weeks	To give the constitutional remedy and observe the changes.
09/12/2023	The Hair loss patches was the same as it was previously but she felt generally better.	Thuja 200/ 3 dose (5 pills /once a week), PL / OD for 3 weeks	Patient felt generally Better.
20/01/2024	Few small hair growth started growing in hair loss patches.	Thuja 200/ 3 dose (5 pills /once a week)	Hair growth started, so repeated same prescription.
17/02/2024	Hair growth standstill otherwise patient was better.	Thuja 200/ 3 dose (5 pills /once a week), PL / OD for 4 weeks	Expected improvement.
30/03/2024	Visible hair growth seen in hair loss patches.	Thuja 1M/stat dose, Pl/ OD for 2 weeks	Improvement standstill, Potency Increased.
13/04/2024	Moderate hair growth in all patches.	Placebo / OD for 2 week	Expected improvement.
27/04/2024	All patches filled with thick density of hair.	Placebo / OD for 1week	Total near cure of Alopecia areata.
06/05/2024 To 06/08/2024	Patient was under the consultation for various minor ailments during this period.	Had given indicated medicines for existing ailments.	Observed 4 months, no recurrence of patches developed.

FIG NO. 1
BEFORE TREATMENT

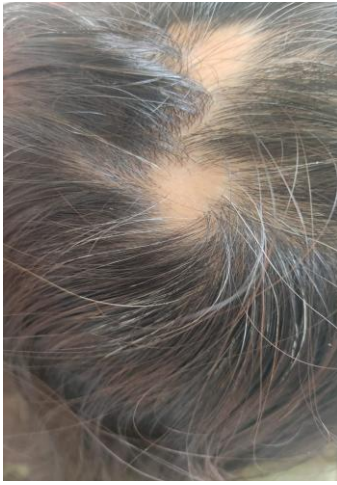

FIG NO. 2
BEFORE TREATMENT

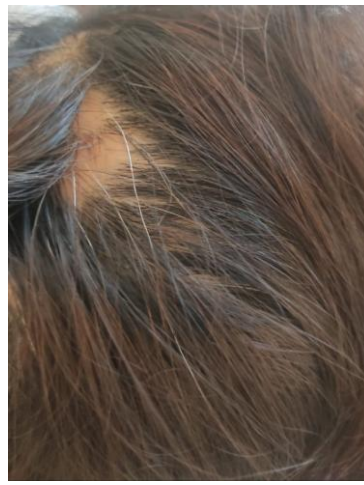

FIG NO. 3
BEFORE TREATMENT

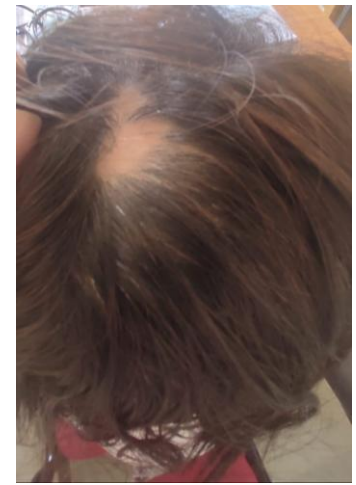


FIG NO. 4
AFTER TREATMENT

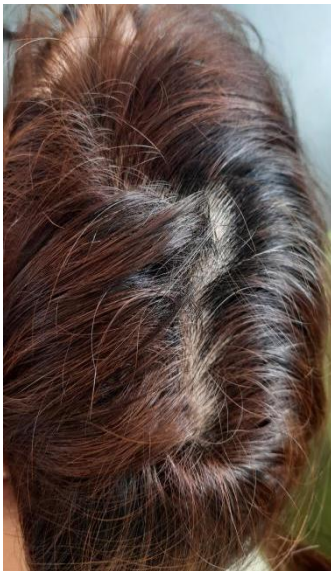

FIG NO. 5
AFTER TREATMENT

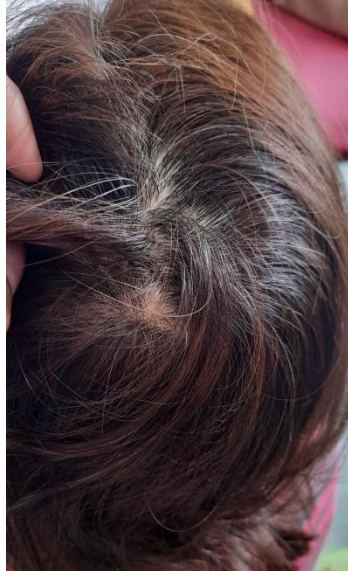

FIG NO. 6
AFTER TREATMENT



RESULTS

The multiple bald patches started having new hair follicles and hence new hair growth. Initially, Thuja 200C did show some improvement. However, much significant improvement was observed later on with higher potency Thuja 1M. The multiple bald patches on the head mostly disappeared within a period of 6-7 months of homoeopathic treatment [Figures 1,2 & 3].

DISCUSSIONS

The patient presented with Alopecia Areata was treated with individualised homoeopathic medicine showed complete hair re-growth without any recurrence in a follow-up period. There is no effective treatment in conventional medicine as such therefore homoeopathy serves the ultimate aid. In this case, after careful history recording, repertorisation and consultation with Materia Medica, Thuja medicine was selected for prescription . Improvement was seen in patient in the beginning which proved correct selection of the remedy and there was little improvement with Thuja 200C. However, marked improvement was observed with higher 1M potency. This case shows the effectiveness of homoeopathic medicine in treating Alopecia Areata when prescribed with individualistic and constitutional approach.

CONCLUSIONS

Homoeopathy is a specialised system of medicine where it treats patient as whole and not just the symptoms. In this case report a complete hair re-growth is observed without any recurrence of bald patches which is recorded as evidence [Figures 4,5 & 6]. This case report shows a positive effect of Homoeopathy in treating Alopecia Areata. However, as this is a single case study and Alopecia Areata is associated with a variable, unpredictable remission so a well-designed studies may be taken up for scientific validation of results.

Informed Consent

The authors certify that they have obtained all appropriate patient consent forms. In the form , the patient has given her consent regarding her images and other clinical information to be reported in the journal and only to conceal her identity, but anonymity cannot be guaranteed.

Conflict of interest

None declared

Financial Support – Nil

REFERENCES

1. Ralston, S.H., Penman, I.D., Strachan, M.W. and Hobson, R.P. (2018) Davidson's Principles and Practice of Medicine. 23rd Edition, Elsevier, Inc., pg 1258 & 1259.

2. Alexandra C Villasante Fricke AC, Miteva M. Epidemiology and burden of alopecia areata: A systematic review. *Clin Cosmet Investig Dermatol*: 2015;8: 397-403.
3. Arthur R, Rook's textbook of dermatology, Edi. Tony, Stephen b, Neil c, Christopher G, Eighth edition, John Wiley Sons, 2010; Vol 4, Chap.66, pp. 66.31-66.38.
4. Shivakumar K, Hair problems answered with homoeopathy, Alopecia Areata, B.jain: New Delhi; 2016. p-46-75.
5. Klaus W, Lowel AG, Stephen IK, Barbara AG, Amy SP, David JL, Fitzpatrick's dermatology in medicine, 7th edi, Mc graw hill, USA; 2008: Vol 1, p762.
6. Gupta MA, Gupta AK, Watteel GA Stress and alopecia areata: a psychodermatologic study, *Acta Dermato-venereologica*.1997, 77(4): 296 -298.
7. Complete repertory of Hompath Classic. Ver. 8.0. Mumbai: Computer Software, Mind Technologies; 2006.
8. Boericke W. Pocket Manual of Homoeopathic Materia Medica and Repertory. New Delhi: B. Jain Publishers Pvt. Ltd; 1994.