



Original Research Article

Volume 7 Issue 4

## A SEVERE HYPERCALCEMIA CASE SECONDARY TO PARATHYROID ADENOMA:

### A CASE REPORT

**Mustafa Dogan**

Istinye University, Medical Park Hospital, Department of Internal Medicine, Samsun,  
Turkey

#### Article history:

Received:

2<sup>nd</sup> November 2018

Received in revised form:

November 2018

Accepted: December 2018

Available online:

December 2018

#### \*Corresponding author:

Mustafa Dogan

Email:

[doganamasya@hotmail.com](mailto:doganamasya@hotmail.com)

#### Present address

Istinye University,  
Samsun Medical Park  
Hospital, Department of  
Internal Medicine,  
55200, Atakum, Samsun,  
Turkey

The authors have no  
conflict of interest to  
declare.

Copyright © 2012

All rights reserved

#### Abstract:

Hypercalcemia is an important health issue with a prevalence of 0.1% and make about 6 of every 1000 acute medical admissions to emergency departments. In present case report, we aimed to discuss a patient with severe hypercalcemia which was secondary to parathyroid adenoma. A 77 year old man presented to outpatient clinics of our institution with complaints of dyspnea, fatigue, tiredness, weakness on all four extremities for 15 days, which worsened by time. His serum calcium was 18 mg/dl. After treatment with intravenous saline, furosemide, zoledronic acid and calcitonin, serum calcium reduced to 8,5mg/dl. An adenoma detected on left lower parathyroid gland in scintigraphy. Physicians should be aware of that primary hyperparathyroidism may manifest with severe hypercalcemia. Aggressive treatment to reduce serum calcium levels is needed until parathyroid surgery is scheduled.

**Keywords:** *Hypercalcemia, parathyroid adenoma, primary hyperparathyroidism*

## INTRODUCTION

Hypercalcemia is an important health issue with a prevalence of 0.1% and make about 6 of every 1000 acute medical admissions to emergency departments (1). Despite there are various causes for hypercalcemia, malignant conditions and hyperparathyroidism are responsible from majority of the cases. It is usually detected in asymptomatic patients during laboratory examinations that ordered because of other reasons. When symptomatic, signs and symptoms include mood disorders, musculoskeletal pain, renal stone, abdominal discomfort, polyuria and polydipsia, obtundation, nausea and/or vomiting, shortening of QT interval or ventricular fibrillation and band keratopathy (2). While treatment of mild cases are treated by the treatment of underlying cause, emergency treatment is needed in severe hypercalcemia (3).

In present case report, we aimed to discuss a patient with severe hypercalcemia which was secondary to parathyroid adenoma.

## Case Report

A 77 year old man presented to outpatient clinics of our institution with complaints of dyspnea, fatigue, tiredness, weakness on all four extremities for 15 days, which worsened by time. He hardly can do his daily work. Urinary and fecal incontinence have begun in last 2 or 3 days. His medical history was relevant for type 2 diabetes mellitus, chronic obstructive pulmonary disease, and right predominant chronic heart failure.

On physical examination, he was lethargic. Systolic and diastolic blood pressures were 110 and 70 mmHg, respectively. His heart rate was 88 beats per minute and rhythmic. He had a tachypnea (24 per minute). His body temperature was 36 celcius degree.

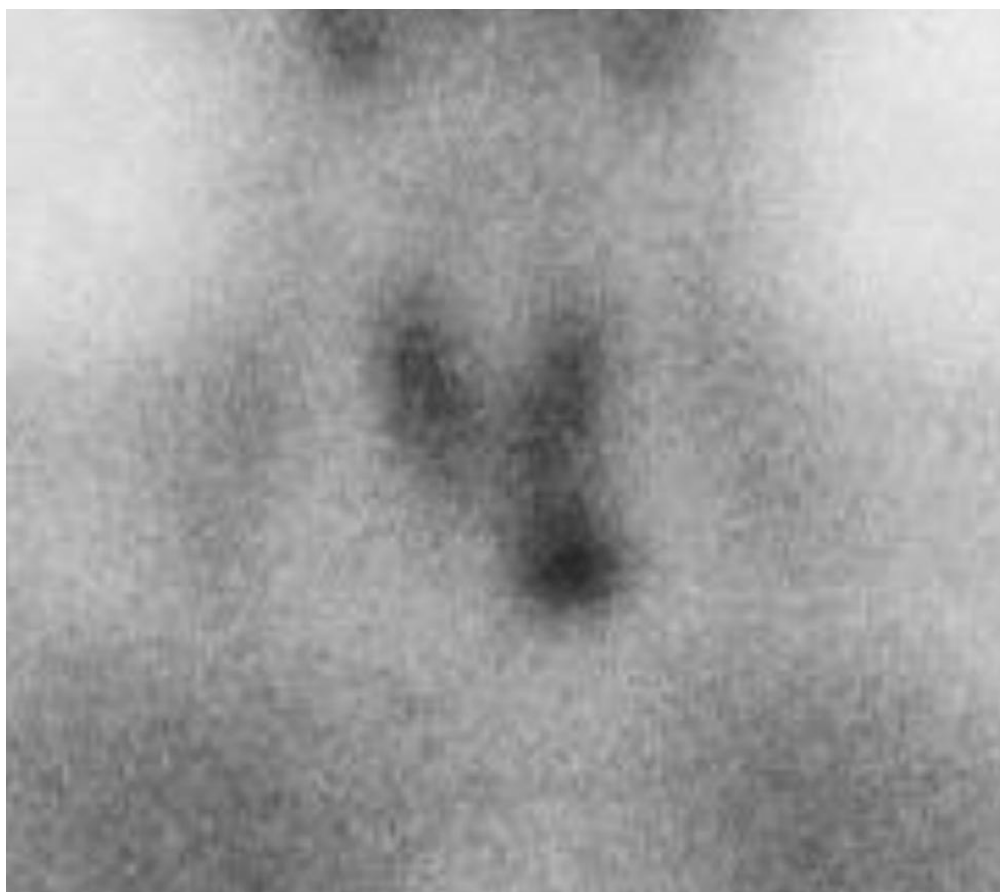
Duration of his expiration was prolonged In auscultation, ronchi heard all over the right and left hemithorax. Bilateral grade 2+ pretibial edema was also noted. Neuromuscular examination revealed bilateral loss of muscle strength in lower extremities (3/5).

Electrocardiography was normal sinusoidal rhythm of 88/min. No QT interval shortening noted. In laboratory analysis of serum, blood glucose was 133mg/dL, HbA1c was 7,4%, uric acid was 13 mg/dL, serum calcium was 18mg/dL (17 mg/dL on repeated test), phosphorus was 2.2 mg/dL (2mg/dL on repeated test), albumin was 3,2g/dL, magnesium was 1.6 mg/dL, parathyroid hormone (PTH) was 1166 pg/ml (reference range: 10-55 pg/ml) and serum 25 OH Vitamin D was 9 ng/ml (reference range:15-45ng/ml). Prostate specific antigen was in normal range.

*International Journal of Nursing and Medical Science 2018; 7 (4), 39-43*

Direct X-ray films of cranium and pelvis was normal, without any lytic lesions. Sonography of the neck was not diagnostic for any pathologies. Thoracolumbar magnetic resonance imaging study, which done because of urinary and fecal incontinence revealed no bone skeleton disorders.

Treatment of severe hypercalcemia done with intravenous hydration with saline and furosemide 20 mg twice daily, after adequate hydration. 40 mg of methylprednisolone administered twice in first day. 4 mg of Zoledronic acid infused intravenously. Calcitonin 300mg four times a daily used for four days. Serum calcium reduced to 13,5mg/dL on 3<sup>rd</sup> day and to 8,5mg/dL on 5<sup>th</sup> day of the treatment. Parathyroid scintigraphy (figure 1) revealed a parathyroid adenoma of 12mm diameter on retrosternal region (lower parathyroid gland on the left). Surgical removal of the adenoma is advised and he transferred to surgery department. He done well after surgery with full recovery of his complaints.



**Figure 1.** Scintigraphy of the patient (adenoma on the left lower parathyroid gland)

## Discussion

In present case study, we reported an interesting severe hypercalcemia case due to PTH secreting parathyroid adenoma, which usually tend to be associated with mild to moderate

hypercalcemia.

Definition of hypercalcemia is elevation of serum calcium 2 standard deviations above the mean of values found in people with normal calcium levels, in at least two samples at least one week apart over a period of three months (4). Severe hypercalcemia term is used when serum calcium is equal to or above 14mg/dl level (5). Serum calcium level of present case on admission was 18 mg/dl, therefore we classified the patient as a severe hypercalcemia case.

The most common underlying etiology in hypercalcemia cases are primary hyperparathyroidism and malignant diseases. Sarcoidosis, milk-alkali syndrome, tertiary hyperparathyroidism, thyrotoxicosis, certain drugs (vitamin D supplements, vitamin A supplements, lithium, thiazides...), immobilization and familial hypocalciuric hypercalcemia are other rare causes of hypercalcemia (2). The present hypercalcemia case was also due to primary hyperparathyroidism.

The most common cause of hypercalcemia, primary hyperparathyroidism, usually occur because of a solitary parathyroid adenoma in 85% of the cases. It may be driven by parathyroid carcinoma (in 1%) or multiple adenomas or parathyroid hyperplasia, too (6). Primary hyperparathyroidism was caused by single gland adenoma in present case which was consistent with literature knowledge.

Asymptomatic mild hypercalcemia (serum calcium  $\geq 10.5$  mg/dL) is usually due to primary hyperparathyroidism and symptomatic, severe hypercalcemia (serum calcium  $\geq 14$  mg/dL) is mainly caused by malignant conditions (5). However, in contrast to literature, symptomatic severe hypercalcemia was caused by a parathyroid adenoma in present case.

Patients with hypercalcemia tend to be hypovolemic due to nephrogenic diabetes insipidus. In treatment of hypercalcemia, hydration and calciuresis should be obtained by intravenous infusion of saline solution followed by furosemide. Bisphosphonates are the treatment of choice for hypercalcemia of malignancy and severe hypercalcemia cases. Since the effects of bisphosphonates occur within 48 to 72 hours, Calcitonin may be helpful in the short-term until bisphosphonates reach therapeutic levels (5). Since emergency treatment is indicated in severe hypercalcemia, in accordance with literature knowledge, we initiated the treatment immediately by administration of the combination of saline hydration, calcitonin, methylprednisolone and zoledronic acid. Serum levels of calcium reduced to normal range within 5 days after aggressive treatment in present case.

In conclusion, we suggest that physicians should be aware of that primary

*International Journal of Nursing and Medical Science 2018; 7 (4), 39-43*

hyperparathyroidism may manifest with severe hypercalcemia. Aggressive treatment to reduce serum calcium levels is needed until parathyroid surgery is scheduled.

**References**

1. Dent DM, Miller JL, Klaff L, Barron J. The incidence and causes of hypercalcaemia. Postgraduate medical journal. 1987;63(743):745-50.
2. Turner JJO. Hypercalcaemia - presentation and management. Clinical medicine (London, England). 2017;17(3):270-3.
3. Walsh J, Gittoes N, Selby P. Emergency management of acute hypercalcaemia in adult patients. Endocrine connections. 2016;5(5):G9-g11.
4. Minisola S, Pepe J, Piemonte S, Cipriani C. The diagnosis and management of hypercalcaemia. BMJ (Clinical research ed). 2015;350:h2723.
5. Cho KC. Electrolyte and Acid-Base Disorders. In: McPhee MAPaSJ, editor. Current Medical Diagnosis and Treatment. 56th ed: McGraw-Hill Education; 2017.
6. Marcocci C, Cetani F. Clinical practice. Primary hyperparathyroidism. The New England journal of medicine. 2011;365(25):2389-97.

**How to cite this article:**

**Mustafa Dogan; Severe hypercalcemia case secondary to Parathyroid Adenoma: A case report; *International Journal of Nursing and Medical Science 2018; 7 (4), 38-43.***